

NATAŠA MILADINOVIĆ-RADMILOVIĆ
The Institute of Archaeology, Belgrade

ANALYSIS OF HUMAN OSTEOLOGICAL MATERIAL FROM THE EASTERN PART OF SITE NO. 37 IN SREMSKA MITROVICA

UDK: 904:726.821(497.113)"09/11"; 902.2:572.7(497.113)"2010"
DOI: 10.2298/STA1262181M
Short communication

e-mail: miladinovic.radmilovic@gmail.com
Received: February 20, 2012
Accepted: June 21, 2012

Abstract. – The direct reason for writing this paper was the new find of skeletons in the medieval necropolis (10th–12th century) discovered as far back 1968 at the Site No. 37 in Sremska Mitrovica (*Sirmium*). Institute for the protection of cultural monuments in Sremska Mitrovica undertook protective archaeological excavations in the eastern part of the site in 2010, discovering 29 skeletons. Since that archaeological analysis of Belo Brdo communities is still in its infancy and considering that there is not a sufficiently big sample for a more precise monitoring of this population's inner dynamics, it is considered useful to present results gained by studying these skeletons on Site No. 37. Although the results in many ways match the results gained up until now, there are some paleopathological changes that so far, have not appeared and for which we had no direct confirmation in the osteological material. One of these paleopathological changes is certainly syphilis.

Key words. – medieval Sirmium, Belobrdo culture, syphilis.

Site No. 37 is located at the corner of Vuk Karadžić and Saint Sava Street in the area of a demolished town prison in Sremska Mitrovica. Protective archaeological excavations were conducted in 1968 and 1969 over the area of 1600 m² (Fig. 1 and 2). On that occasion a section of the northern wing of the Sirmium imperial palace was explored, as well as a Gepidian cultural layer from the 5th century and a part of a medieval necropolis with skeletal burials from 10th–12th century.¹ Finds from this necropolis belong to the Belobrdo culture.²

Between 1957 and 2007, graves from 10th–12th century, containing Belo Brdo culture materials were discovered in Sremska Mitrovica, on the total of 11 sites (Fig. 1 and 2). Those are Sites No. 4, 25, 34, 35, 37, 66,

83 and 85, Južni bedem, Mačvanska Mitrovica,³ and Site Trasa kanalizacije – Dositejeva Street. Unfortunately, only 82 skeletons were available for anthropological analysis (from Site No. 83 (nine individuals), Site No. 85 (65 individuals), Južni bedem (two individuals),

¹ Osteological material of human origin from this site was sent to USA for anthropological expertise in the 1970's. Unfortunately, the results of these analyses have not yet been delivered to the Museum of Srem in Sremska Mitrovica or Institute of Archaeology in Belgrade. Likewise, they have not been published, as far as the author of this text is informed.

² Милошевић 1994, 31.

³ Tomičić 2010, 121, 128, 133–135, Tab. 27.

* This article is the result of the projects: *Romanization, urbanization and transformation of urban centres of civil, military and residential character in Roman provinces on the territory of Serbia* (No. 177007) and *Urbanization Processes and Development of Medieval Society* (No. 177021) founded by the Ministry of Education, Science and Technological Development of the Republic of Serbia.

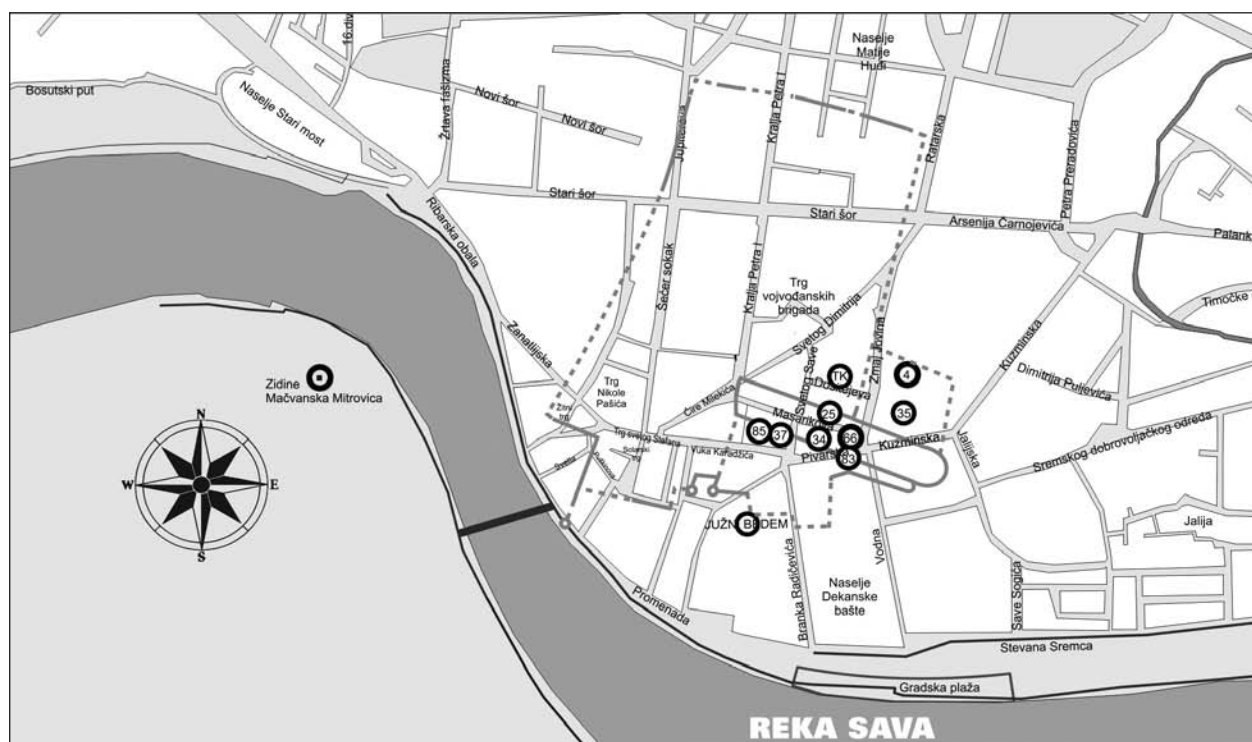


Fig. 1. Map of Sremska Mitrovica, necropolis from 10th–12th century⁴

Сл. 1. Карта Сремске Митровице, некрополе X–XII века

Mačvanska Mitrovica (five individuals) and Site Trasa kanalizacije – Dositejeva Street (one individual)).⁵

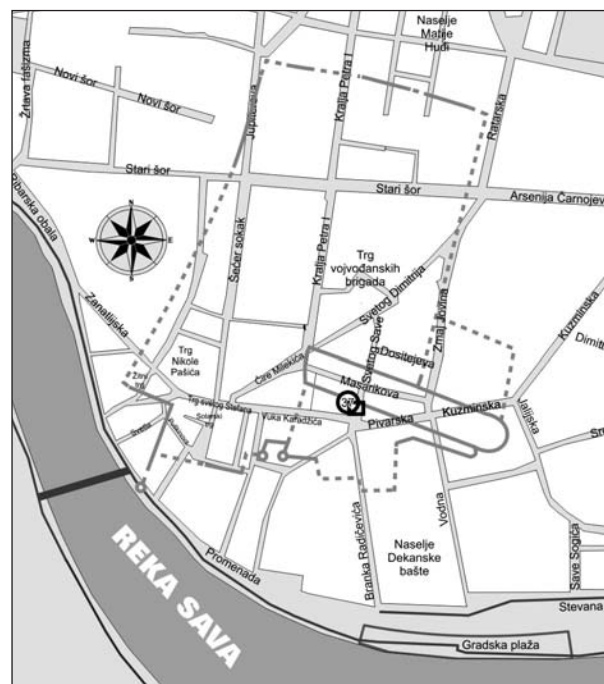
In September 2010, a team from the Institute for the protection of cultural monuments in Sremska Mitrovica undertook protective excavations in the Saint Sava Street. On that occasion a sonde, measuring 4 x 4 m was opened (Figs. 3–6). Eighteen graves and four groups of dislocated bones were discovered (29 skeletons in total). Skeletons were mostly oriented southwest-northeast. The deceased were laid on their backs with arms beside their bodies. A number of iron nails were discovered, leading archaeologists to the conclusion that the deceased had been buried in wooden coffins.⁶

MATERIAL

Osteological material of human origin from previous excavations on Site No. 37 was, as mentioned, unavailable for analysis, so it was decided to present the analysis of all 29 individuals (Table 1) thus contributing towards creating a general picture of this population.

Fig. 2. Map of Sremska Mitrovica, Site No. 37

Сл. 2. Карта Сремске Митровице, локалитет 37



Of course, a broad archaeological and chronological dating represented a great difficulty in anthropological reconstruction and interpretation (10th–12th century) contributed by, among other things, a large number of finds discovered in the necropolises which were not chronologically sensitive, as was outlined, as well as an insufficient number of skeletons discovered. Therefore, it was impossible to observe the inner dynamics of this population more precisely even when the site i.e. the necropolis is uncovered totally or to a great extent, as opposed to colleagues in our region that have been successfully engaged in this enterprise.⁷

METHODOLOGICAL FRAMEWORK

The examined degree of skeleton preservation is given in the form of descriptive schemes consisting of five categories proposed by Mikić:⁸ I – the whole skeleton is well preserved; II – well-preserved, incomplete skeleton; III – moderately preserved skeleton;⁹ IV – partial preservation of skeletal remains¹⁰ and V – poor preservation of skeletal remains.¹¹

In determining sex in children, we put emphasis on the study of morphological elements of the mandible (protrusion of *protuberantiae mentalis*, the shape of the alveolar part, protuberance in the *gonion* area) and pelvis (the angle of a greater sciatic notch, the position of the pelvic arch, the curvature of *cristae iliacae*). The methodology was based on data obtained by Schutkowski during his extensive research.¹²

For sex determination on skeletal materials of adult individuals we adopted for a combination of morphological and metrical methods. Specific attention was being paid on morphological elements of the skull (*glabella*, *planum nuchale*, *processus mastoideus*, *processus zygomaticus*, *arcus superciliaris*, *protuberantia occipitalis externa*, *os zygomaticum*, *tubera frontale et parietale*, inclination of *os frontale*, *margo supraorbitalis* and shape of *orbitae*) and the pelvis (*sulcus praearicularis*, *incisura ischiadica s. ischialis major*, *arcus pubis s. pubicus et angulus subpubicus*, *arc compose*, the appearance of *os coxae*, *corpus ossis ischii*, *foramen obturatum*, *crista iliaca*, *fossa iliaca*, *pelvis major*, *pelvis minor*; subpubic region: ventral arc, subpubic concavity and medial appearance of the ischio-pubic branch), whereas the method of operation was adopted from a group of European anthropologists,¹³ Buikstra and Ubelaker.¹⁴ Morphological elements were also analyzed on the mandible (the overall appearance of mandible

(*corpus mandibulae*, *ramus mandibulae* and *angulus mandibulae*), *mentum*, *angulus mandibule* and *margo inferior*), based on criteria defined by Ferembach and his associates,¹⁵ and metric elements relevant for sex determination in skeletons.¹⁶ Indices, calculated on the basis of gained metric elements, were shown in tables for each grave individually. Teeth were measured for mesio-distal and vestibulo-lingual diameters using a method approved by Hillson.¹⁷ According to these diameters difference in teeth size was monitored mostly on canines; should they be missing from osteological material, other teeth would suffice (molars, premolars and incisors).¹⁸ Morphological and metric elements were observed during analysis of other postcranial bones as well. Morphological elements that caught the most of our attention were degrees of development of: *tuberositas deltoideae*, *tuberositas radii* and *margo interosseus* (of the radius), *tuberositas ulnae* and *margo interosseus* (of the ulna), *linea aspera* and *tuberositas tibiae*. Bone appearance, body curvature and *facies auricularis* were morphological elements observed in sacrum.¹⁹ Metric elements played a more

⁴ All photographs of humane osteological material were taken by N. Miladinović-Radmilović. Postproduction and electronic processing of situation plans from the field documentation of the Institute for the Protection of Cultural Monuments from Sremska Mitrovica and map making were done by M. Radmilović.

⁵ Miladinović-Radmilović 2011, 465–510.

⁶ The data was taken from the field documentation of the Institute for the Protection of Cultural Monuments in Sremska Mitrovica.

⁷ Vodanović, Brkić, Demo i Šlaus 2003; Vodanović, Brkić i Demo 2004; Bedić i Novak 2010.

⁸ Mikić 1978, 9.

⁹ Medium preservation refers to the situation where an entire skeleton is present inside the grave, but the bones are brittle and brake during excavation.

¹⁰ Partial preservation refers to the situation where the grave contains only parts of a skeleton that are very brittle and difficult to lift, pack and transport.

¹¹ Poor preservation refers to the situation where the remains of a skeleton exist only in traces and are virtually impossible to lift completely.

¹² Schutkowski 1993.

¹³ Ferembach, Schwidetzky and Stloukal 1980, 519–527.

¹⁴ Buikstra and Ubelaker 1994, 15–21.

¹⁵ Ferembach, Schwidetzky and Stloukal 1980, 523–525.

¹⁶ Ferembach, Schwidetzky and Stloukal 1980, 523–525; Bass 1995, 84, 85.

¹⁷ Hillson 1990, 240–242; *idem*. 1996, 80–82.

¹⁸ Garn, Lewis and Kerewsky 1965.

¹⁹ Mikić 1978, 18, 19; Bass 1995, 114.

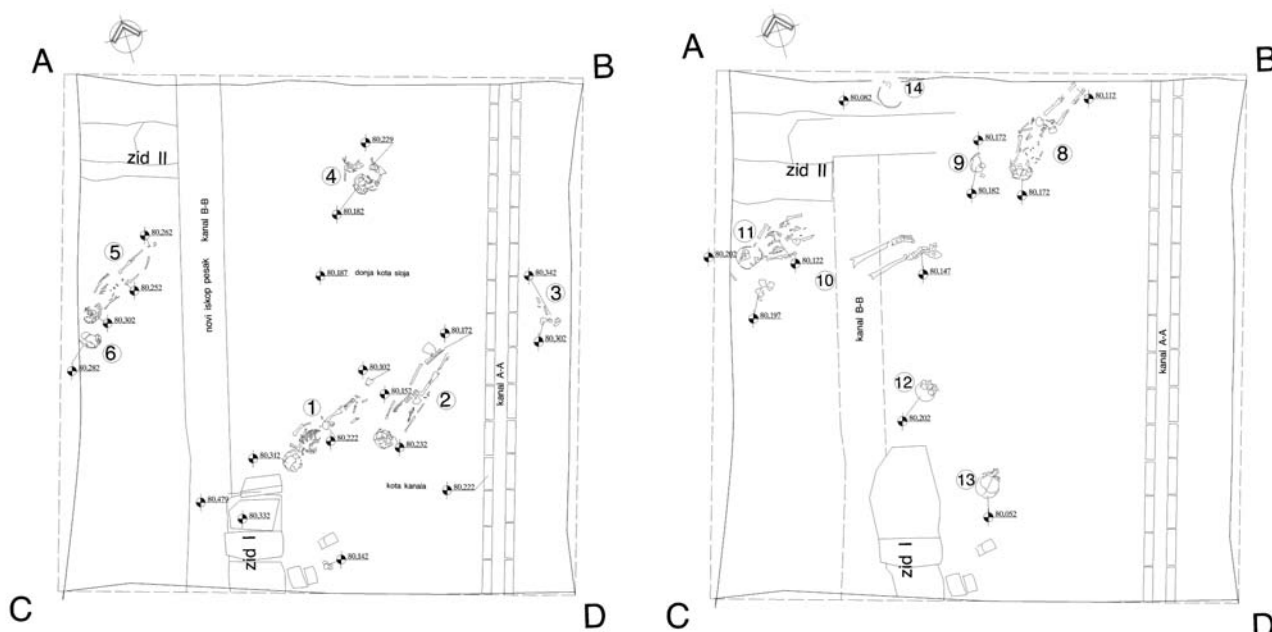


Fig. 3. Sonde 1, position of graves 1, 2, 3, 4, 5 and 6²⁰
 Fig. 4. Sonde 1, position of graves 8, 9, 10, 11, 12, 13 and 14²¹
 Сл. 3. Сонда 1, положај гробова 1, 2, 3, 4, 5 и 6
 Сл. 4. Сонда 1, положај гробова 8, 9, 10, 11, 12, 13 и 14

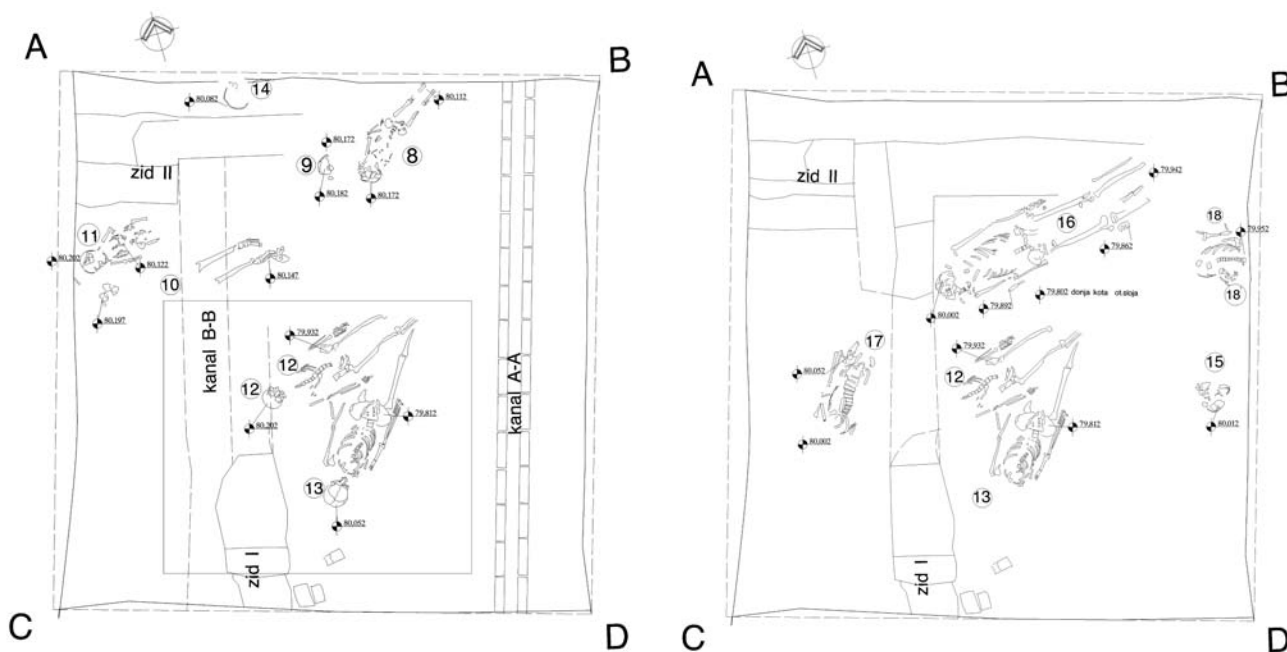


Fig. 5. Sonde 1, position of graves 8, 9, 10, 11, 12, 13 and 14²²
 Fig. 6. Sonde 1, position of graves 12, 13, 15, 16, 17 and 18²³
 Сл. 5. Сонда 1, положај гробова 8, 9, 10, 11, 12, 13 и 14
 Сл. 6. Сонда 1, положај гробова 12, 13, 15, 16, 17 и 18

significant role in sex determination based on postcranial skeleton, and they were given additional attention. Indices calculated on the basis of gained metric elements were shown in tables for each grave individually, and for left and right side separately.

Individual age estimation in children was based on degree of formation and teeth eruption (Ubelaker scheme);²⁴ degree of ossification of the epiphysis-diaphysis connections (Table with time scales (years) during which epiphysis-diaphysis connections ossify);²⁵ length of long bones (tables (with time scales shown in years and months) defined by Bass²⁶ and Ferembach with associates).²⁷

Individual age in adults was established upon: degree of obliteration of local skull sutures (Vallois' scheme);²⁸ changes in maxilla and mandible teeth (changes in occlusal surface on the dental material was compared with the numerical classification of attrition of the upper (occlusal) surface of molars in relation to age which was defined by Brothwell²⁹ and changes on occlusal surface of all teeth in relation to age defined by Lovejoy;³⁰ morphological changes in sternal ends of ribs (metamorphoses of depth, joint cavities, shape, edges and ridge configuration were examined, together with overall state of bone, based on ten (0–8) phases of progression covering the period from 18 to over 70 years);³¹ morphological changes on the medial end of the clavicle (morphological changes of the clavicle documented by Scheuer and Black were observed).³² They established five (1–5) phases of progression covering periods lasting from 14 to 29 years); morphological changes in pubic symphysis joint surface (Todd's method was used in which the metamorphosis of the pubic symphysis surface is divided in ten chronological phases during aging, starting with age 18 and leading up to age 50 and over);³³ sacroiliac region (individual age of adult individuals was determined upon models defined by Lovejoy and his associates.³⁴ They classified the changes in this region in eight stages, from late adolescence to old age phase, with most attention directed to observation of position, edge *lip-ping* and porosity of the bone in this region).

Twenty-six epigenetic variations on the cranium and eleven on the postcranial skeleton were observed.³⁵

Stature in children and juvenile (*juvenilis I*) individuals was calculated using a formula defined by Maresh,³⁶ whereas for juvenile (*juvenilis II*) and adult individuals Trotter and Gleser's formulas were used.³⁷

HUMAN OSTEOLOGICAL MATERIAL FROM EASTERN PART OF SITE NO. 37

Grave 1

Skeletal remains of a female (?) child aged 18 (?) months were discovered in the grave (Figs. 3, 7a and 7b; Tables 1 and 2).³⁸

Paleopathological changes that can be observed on the cranial part of the skeleton are porotic hyperostosis and traces of tuberculosis on the ribs. Postcranial bones exhibit some sort of dysplasia (*achondroplasia*?). Namely, thickening of the cortex and noticeable enlargement of mediolateral diameter is perceived in the region of long-bones' diaphysis and metaphysis (Figs. 7a and 7b). Severe body curvature is solely observed in the left fibula. Deeper lesions are perceived on the anterior and posterior side of the iliac part of the left pelvic area, as well as on all muscle attachment points and long postcranial bones.

Grave 2

The grave contained remains of a male child individual, aged four and a half,³⁹ and a child individual,

²⁰ Field documentation of the Institute for the Protection of Cultural Monuments in Sremska Mitrovica.

²¹ Field documentation of the Institute for the Protection of Cultural Monuments in Sremska Mitrovica.

²² Field documentation of the Institute for the Protection of Cultural Monuments in Sremska Mitrovica.

²³ Field documentation of the Institute for the Protection of Cultural Monuments in Sremska Mitrovica.

²⁴ Ferembach, Schwidetzky and Stloukal 1980, 528, 529.

²⁵ Ferembach, Schwidetzky and Stloukal 1980, 531.

²⁶ Bass 1995, 155, 168, 176, 228, 247, 257.

²⁷ Ferembach, Schwidetzky and Stloukal 1980, 532.

²⁸ Vallois 1937.

²⁹ Brothwell 1981, 72.

³⁰ Lovejoy 1985.

³¹ Işcan, Loth and Wright 1984a; *idem.* 1984b; *idem.* 1985.

³² Scheuer and Black, 2000.

³³ Todd 1920, 285–334; *idem.* 1921a; *idem.* 1921b.

³⁴ Lovejoy *et al.* 1985.

³⁵ Hauser and De Stefano 1989; Ђуринћ-Срејић 1995, 238–260.

³⁶ Walker and Pérez-Pérez, 18.

³⁷ Trotter and Gleser 1952.

³⁸ Degree of bone preservation: II category (a well preserved incomplete cranial and postcranial skeleton).

³⁹ Degree of bone preservation: II category (a well preserved incomplete cranial and postcranial skeleton).

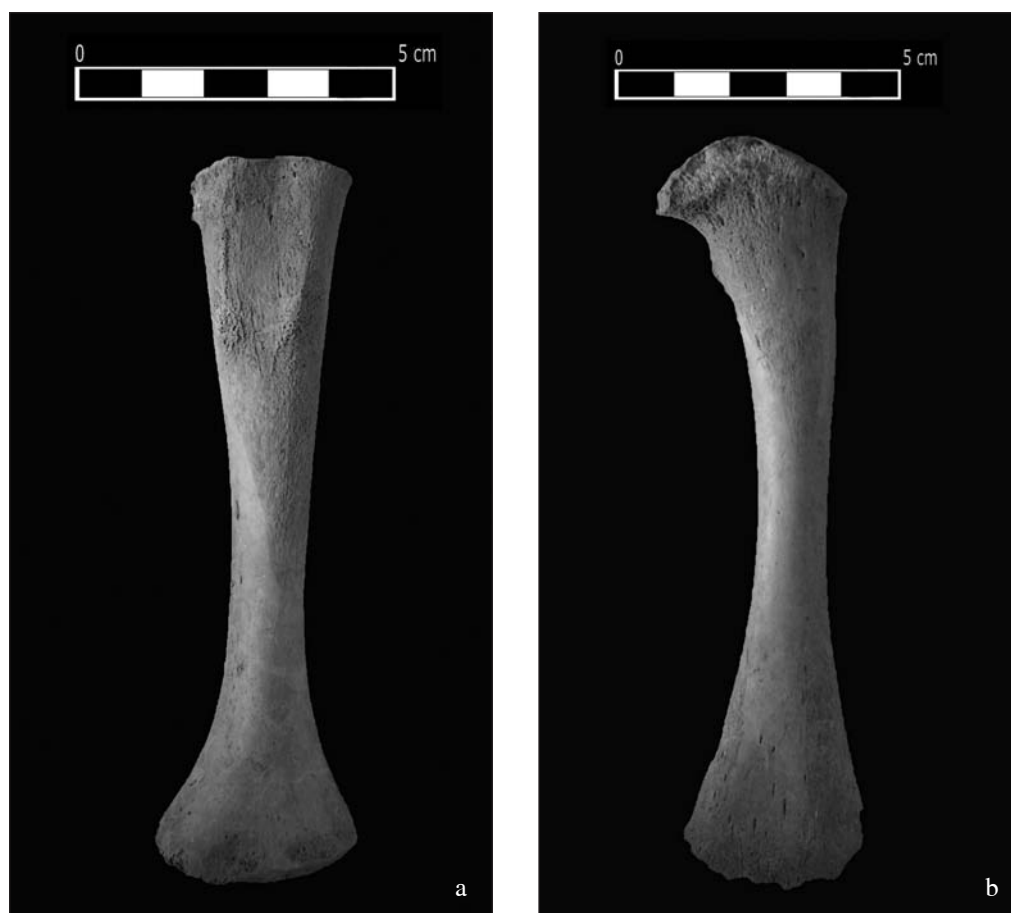


Fig. 7. Grave 1, dysplasia (achondroplasia?): a) of the left humerus; b) of the left femur
Сл. 7. Гроб 1, дисплазија (achondroplasia?): a) левої хумеруса; b) левої фемура



Fig. 8. Grave 2: a) cribra femora; b) traces of tuberculosis on ribs
Сл. 8. Гроб 2: a) criбра фемура; b) шрапови туберкулозе на ребрима

of undetermined sex, aged around 30 months (Figs. 3, 8a and 8b; Tables 1 and 2).⁴⁰

Perceived paleopathological changes in the older individual are porotic hyperostosis (on parietal bones) *cribra femora* near the upper end of the left and right femur on the anterior side (measuring 1 x 2 cm) and a trace of tuberculosis on the one preserved rib (Figs. 8a and 8b).

A noticeable epigenetic characteristic on *norma frontalis* are *sulci frontales* (one on the left side), and on *norma lateralis* – two *foramen zygomaticofaciale* (on the left zygomatic bone). *Trochanter tertius* was noticed on the right femur of the postcranial skeleton.

No paleopathological changes were noticed in the younger child. *Tuberositas radii* is somewhat more prominent than usual.

Grave 3

The grave contained skeletal remains of a child of undetermined sex and age,⁴¹ and an adult individual of undetermined sex and age (Fig. 3; Table 1).⁴²

No paleopathological changes were noticed in these individuals.

Grave 4

The grave contained skeletal remains of a child of undetermined sex, aged three and a half (Fig. 3; Tables 1 and 2).⁴³

No paleopathological changes were noticed. The appearance of *suturæ metopicae* on *norma frontalis* is a perceived epigenetic characteristic.

Grave 5

The grave contained skeletal remains of a female child aged 2 years ± 8 months,⁴⁴ and an adult individual of undetermined sex and age (Fig. 3; Tables 1 and 2).⁴⁵

Perceived paleopathological changes in the child individual are *cribra femora* near the upper end of the right and left femur on the anterior side (1cm in diameter), resorption of cortical tissue at the muscle attachment point *m. triceps brachii – Caput laterale* (right humerus), *m. biceps brachii* (right and left radius), *m. iliopsoas* and at the point of attachment of all muscles along *linea aspera* (right and left femur), dislocation of the left ankle and a possible middle ear inflammation accompanied by an infection.

Epigenetic characteristics noticed on *norma lateralis* are two *foramen zygomaticofaciale* on the right zygomatic bone.

No paleopathological changes were noticed in the adult individual.

Grave 6

The grave contained skeletal remains of a male (?) child aged 3 years ± 12 months (Figs. 3, 9a and 9b; Table 1).⁴⁶

Perceived paleopathological changes are *cribra orbitalia* on orbital roofs and porotic hyperostosis on *lamina externa* on all preserved cranial bones except the occipital bone (Fig. 9a). Changes similar to those caused by metabolic processes (scurvy or rickets) were noticed on *lamina interna* of the occipital and left parietal bone. Likewise, there is a possible ear inflammation accompanied by an infection, similar to individual from grave 5 (Fig. 9b).

Grave 8⁴⁷

The grave contained skeletal remains of a female child, aged three,⁴⁸ and an adult or a juvenile individual of unknown sex and age (Figs. 4, 5 and 10; Tables 1 and 2).⁴⁹

Perceived paleopathological changes in the child are ellipsoidal bony protuberance on one rib fragment (measuring 0.8 x 0.5 cm), deeper lesions in the upper third of the body of the left humerus on the anterior side (the affected bone area measures 1 x 2.5 cm; Fig. 10) and *cribra femora* near the upper ends on the anterior side of the femur (0.7 cm in diameter).

⁴⁰ Degree of bone preservation: II category (a well preserved incomplete postcranial skeleton).

⁴¹ Degree of bone preservation: II category (a well preserved incomplete cranial skeleton).

⁴² Degree of bone preservation: II category (a well preserved incomplete postcranial skeleton).

⁴³ Degree of bone preservation: II category (a well preserved incomplete cranial and postcranial skeleton).

⁴⁴ Degree of bone preservation: II category (a well preserved incomplete cranial and postcranial skeleton).

⁴⁵ Degree of bone preservation: II category (a well preserved incomplete cranial and postcranial skeleton).

⁴⁶ Degree of bone preservation: II category (a well preserved incomplete cranial and postcranial skeleton).

⁴⁷ In a so-called grave 7 only animal skeletal remains were discovered. It should be mentioned that in graves 1, 4, 5, 8, 9, 10, 12, 16 and 17, as well as among dislocated bones I–III numerous animal bone fragments were found, most likely offerings.

⁴⁸ Degree of bone preservation: II category (a well preserved incomplete cranial and postcranial skeleton).

⁴⁹ Degree of bone preservation: II category (a well preserved incomplete postcranial skeleton).




Fig. 9. Grave 6: a) porotic hyperostosis; b) possible ear inflammation accompanied by infection

Fig. 10. Grave 8: deep lesions on the left humerus

Сл. 9. Гроб 6: а) порозна хиперостоза; б) могућа ујала уха праћена инфекцијом

Сл. 10. Гроб 8: дубље лезије на левом хумерусу

No paleopathological changes were noticed in the adult individual

Grave 9

The grave contained skeletal remains of a child individual, of unknown sex and age (Figs. 4 and 5; Table 1).⁵⁰

Cribra orbitalia was a paleopathologic find noticed on the left orbit roof.

Grave 10

The grave contained skeletal remains of a male adult individual, of unknown age (Figs. 4 and 5; Tables 1 and 8).⁵¹

Perceived paleopathological changes are irregularly fused fracture of the II metatarsal bone (in the upper half of the body), injury to the right tibia (on the middle of *margo anterior*, a bony protuberance 1 x 0.5 cm in size can be noticed, and an infection on the lower end on the

⁵⁰ Degree of bone preservation: II category (a well preserved incomplete cranial skeleton).

⁵¹ Degree of bone preservation: II category (a well preserved incomplete postcranial skeleton).

medial and posterior side), osteoarthritis and the dislocation of both ankles (may have occurred as a result of difficulties in movement due to the injury to the right tibia) and the possible emergence of the so-called bunion.

Grave 11

The grave contained skeletal remains of a male child aged two and a half (Figs. 4 and 5; Tables 1 and 2).⁵²

Perceived paleopathological changes are middle ear inflammation and *cribra femora* near the upper ends on the anterior side of both femurs (1.5 and 1 cm in diameter).

Noticable epigenetic characteristic on *norma occipitalis* are *ossa suturae lambdoideae* (one on the left side 1.3 x 1 cm in size).

Grave 12

The grave contained skeletal remains of a female, adult individual, aged between 33–46 (Figs. 4–6, 11 and 12; Tables 1, 3–8).⁵³

Noticeable paleopathological changes are a mild form of osteoarthritis (on the condyles of the mandible, on several thoracic vertebrae on the upper end of the right ulna and on right tibia's tuberositas), aneurism (?) on the medial end of the right clavicle (1.5 cm in diameter) and bony outgrowths (0.5 and 0.2 cm in diameter) on the right tibia's *facies medialis*.

Dental analysis showed the presence of the following teeth: 16, 18, 26, 31, 32, 33, 34, 35, 37, 38, 43 and 44. Teeth 17, 25, 28, 36, 46 and 47 (Figs. 11 and 12) were lost antemortem, teeth 14, 15, 24, 27 (?), 41, 42 and 45 postmortem. Abrasion of the 1st degree (in enamel) was discovered in teeth 16, 35 and 44 (→II), 2nd degree (exposed dentin) on 34, and 3rd degree (to the bottom of the fissure) on teeth 31, 32, 33 and 43). Periodontal disease and calculus were highly prominent (due to a large presence of calculus, the possible appearance of hypoplasia was unobservable). Teeth rotation was the only present anomaly concerning mandible and dental arch). Caries was present in teeth: 17 (mesial, caries 0.7 cm in diameter), 26 (the so-called gross-gross caries), 38 (occlusal, caries in the shape of dot) and 48 (occlusal, caries in the shape of dot). Occlusion could not be determined.

Epigenetical characteristics noticeable on *norma frontalis* are *sulci frontales* (two on the left side) and *linea nuchae suprema* (very prominent) on *norma occipitalis*. On the postcranial part of the skeleton, *trochanter tertius* was noticed on the right femur beside *foramen processus transversi bipartitum* (C6).

Markers of occupational stress in the form of hypertrophy (cortical defect) were present on the muscle attachment points of the right and left clavicle (*m. deltoideus*), right scapula (*m. triceps brachii – Caput longum*, *m. subscapularis*, *m. infraspinatus*, *m. teres minor*, *m. teres major*), left scapula (*m. triceps brachii – Caput longum*, *m. subscapularis*, *m. infraspinatus*, *m. teres minor*, *m. teres major*, *m. deltoideus*, *m. biceps brachii – Caput longum*, *m. biceps brachii – Caput breve*, *m. serratus anterior*, *m. rhomboideus minor*, *m. rhomboideus major*), right humerus (*m. brachioradialis*, *m. extensor carpi radialis longus*, *m. extensor carpi radialis brevis*, *m. extensor digitorum*, *m. extensor digiti minimi*, *m. extensor carpi ulnaris*, *m. supinator*, *m. pronator teres*), left humerus (*m. brachioradialis*, *m. extensor carpi radialis longus*, *m. extensor carpi radialis brevis*, *m. extensor digitorum*, *m. extensor digiti minimi*, *m. extensor carpi ulnaris*, *m. supinator*, *m. pronator teres*, *m. supraspinatus*, *m. subscapularis*, *m. latissimus dorsi*, *m. pectoralis major*, *m. teres major*, *m. deltoideus*, *m. coracobrachialis*, *m. brachialis*), right radius (*m. adductor pollicis longus*,⁵⁴ *m. biceps brachii*), left radius (*m. adductor pollicis longus*, *m. biceps brachii*), right ulna (*m. supinator*, *m. brachialis*, *m. pronator teres*, *m. flexor digitorum superficialis*, *m. triceps brachii*; olecranon was slightly separated), left ulna (*m. supinator*, *m. brachialis*, *m. pronator teres*, *m. flexor digitorum superficialis*), both femurs (all attachment points are prominent along *lineae asperae* and near the lower end on the posterior side) and both fibulae (*m. flexor hallucis longus*). Markers of occupational stress in the form of hypertrophy (cortical defect) were present on attachment points of right clavicle's ligaments (*lig. trapezoideum*, *lig. conoideum*) and left clavicle (*lig. trapezoideum*, *lig. conoideum*, *lig. costoclaviculare*).

Specific observations: the emergence of batrocran; *foramen mandibulae* is larger (1 cm in diameter); condyle is extremely large in size (3.3 x 2.25 cm); *facies articularis tuberculi costae* is disk-shaped (1.3 cm in diameter) with a perforation in the middle.

⁵² Degree of bone preservation: II category (a well preserved incomplete cranial and postcranial skeleton).

⁵³ Degree of bone preservation: II category (a well preserved incomplete cranial and postcranial skeleton).

⁵⁴ There is a bony protuberance 1 x 2 cm in size on the attachment point of this muscle.

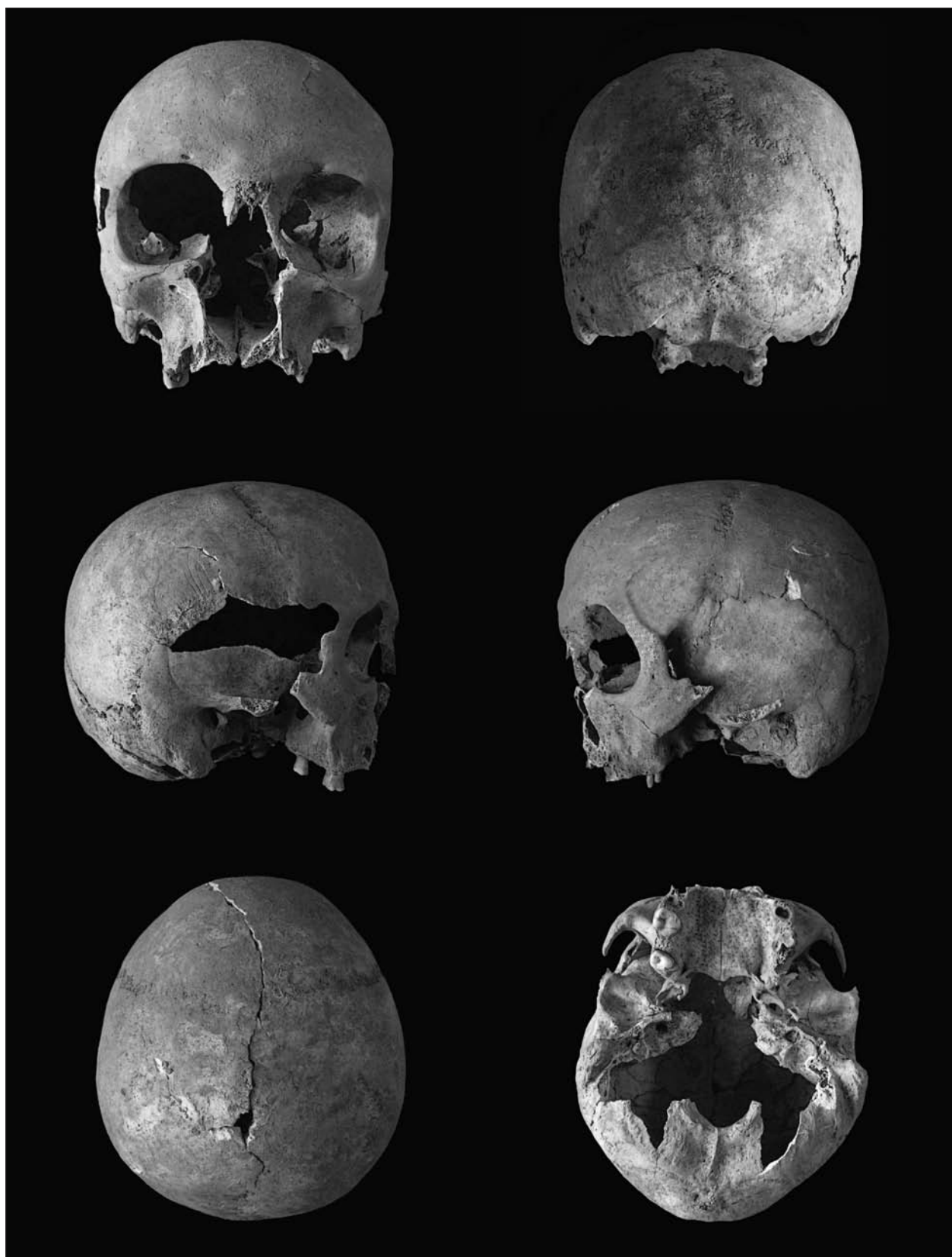


Fig. 11. Grave 12: skull projections

Сл. 11. Гроб 12: лобањске пројекције

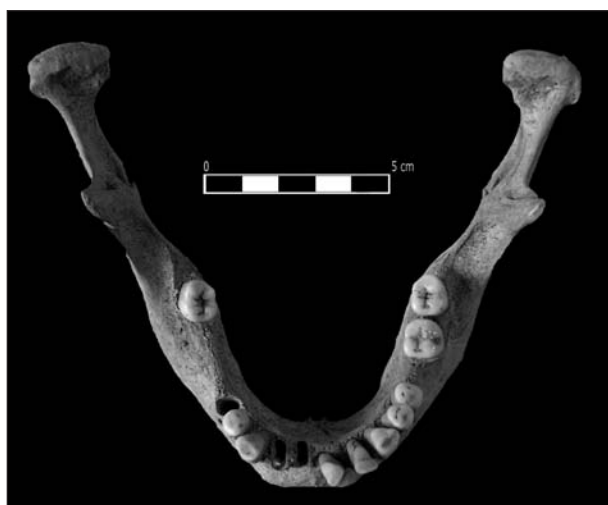

Fig. 12. Grave 12: mandible

Сл. 12. Гроб 12: мандибула

Grave 13

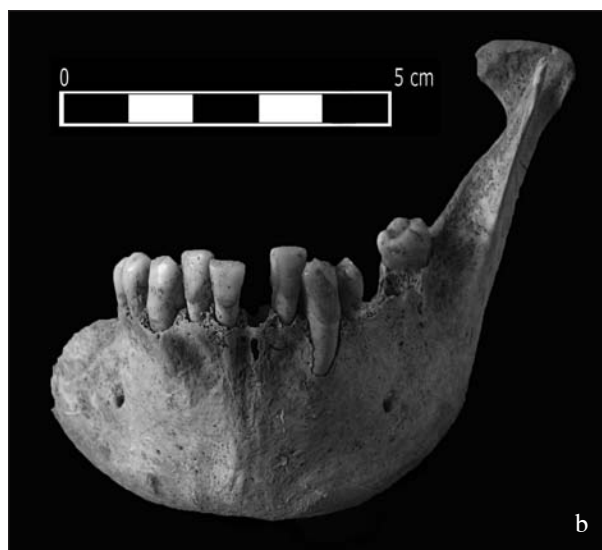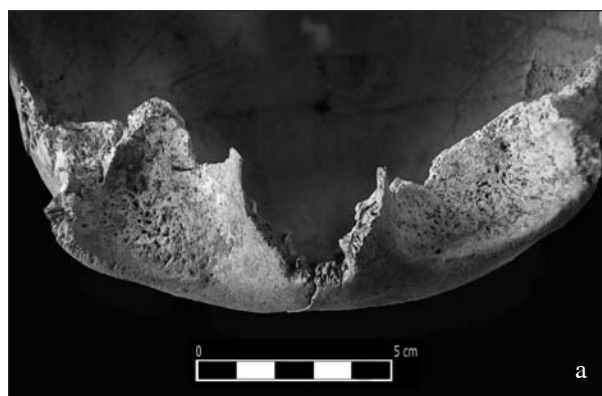
The grave contained skeletal remains of a male adult individual aged around 25 (Figs. 4–6, 13a and 13b; Tables 1, 3–8).⁵⁵

Noticable paleopathological changes are *cribra orbitalia* (on orbit roofs; Fig. 13a) Schmorl's defect on thoracic vertebrae, dislocation of both knees, *osteo-chondritis dissecans* near the upper end of the right femur on the anterior side (2.5 x 0.2 cm in size) and an osteoma on the right side of the mandible, close to the mentum, below the tooth 43 (0.5 cm in diameter).

Dental analysis showed the presence of the following teeth in the mandible (Fig. 13b): 32, 33, 34, 38, 41, 42, 43, 44 and 45. Teeth 36, 46 and 47 were lost antemortem, teeth 31, 35 and 37 postmortem. Abrasion of the 1st degree (in enamel) was discovered in teeth 32, 41 and 42. Periodontal disease was highly prominent, and the calculus varied from medium to highly prominent, and hypoplasia was slightly prominent. Cysts were noticed on the buccal side of teeth 36 (1.1 cm in diameter) and 37 (1.3 cm in diameter). A mild inward dislocation of teeth 32 and 42 is the only anomaly concerning mandible and dental arch. No caries was noticed. Occlusion could not be determined.

Noticeable epigenetic characteristics on *norma lateralis* are three *foramen-a zygomaticofaciale* on the left zygomatic bone.

Markers of occupational stress in the form of hypertrophy (cortical defect) were present on the muscle attachment points of the right scapula (*m. deltoideus*),

Fig. 13. Grave 13: a) *cribra orbitalia*; b) mandibleСл. 13. Гроб 13: a) *cribra orbitalia*; b) мандибула

left scapula (*m. triceps brachii – Caput longum*, *m. subscapularis*, *m. infraspinatus*, *m. teres minor*, *m. teres major*), left humerus (*m. brachioradialis*, *m. extensor carpi radialis longus*, *m. extensor carpi radialis brevis*), both radiuses (*m. biceps brachii*), both ulnae (*m. supinator*, *m. brachialis*, *m. pronator teres*, *m. flexor digitorum superficialis*, *m. triceps brachii*), both femurs (all muscle attachment points are prominent in the upper third of *lineae asperae* at the lower end on the posterior side) and both tibiae (*m. sartorius*, *m. gracilis*, *m. semitendinosus*).

⁵⁵ Degree of bone preservation: II category (a well preserved incomplete cranial and postcranial skeleton).

Grave 14

Skeletal remains of a juvenile individual, of unknown sex, aged between 13–16 (Figs. 4 and 5; Table 1).⁵⁶

No paleopathological changes were noticed.

Epigenetical characteristics noticeable on *norma verticalis* are *foramina parietalia* (one on each of parietal bones) and *ossa suturae lambdoideae* on *norma occipitalis* (one on the right side, 0.5 x 0.7 in size, and one on the left side, fairly decomposed).

Grave 15

The grave contained skeletal remains of a male, adult individual, aged between 20–24,⁵⁷ and a child, of unknown sex and age (Fig. 6; Tables 1 and 5).⁵⁸

The only paleopathological change noticed in the adult individual, is one similar to *cribra* on *lamina interni* on the frontal bone.

Teeth analysis revealed teeth 41, 43, 45, 46 and 47 present in the mandible. 42 and 44 were lost postmortem. Abrasion of the 1st degree (in enamel) as perceived in teeth 41 and 43. Periodontal disease was mild to moderate, calculus was moderate, and hypoplasia was mild. Hypodontia on tooth 48 was the only jaw and dental arch related anomaly. Caries was noticed in teeth 46 (occlusal, caries shaped as two dots) and 47 (occlusal, caries shaped as a dot, 0.1 cm in diameter). Occlusion could not be determined.

Epigenetical characteristics noticeable on *norma frontalis* are *sulci frontales* (one on the left parietal bone) and *ossa suturae lambdoideae* on *norma occipitalis* (one on the right side, 0.7 x 2 cm in size, and *linea nuchae suprema* (very prominent).

Markers of occupational stress in the form of hypertrophy (cortical defect) were present on the muscle attachments of the left scapula (*m. deltoideus*, *m. triceps brachii* – *Caput longum*, *m. teres minor*, *m. teres major*). Occupational stress markers in the form of hypertrophy (cortical defect) were present in ligament attachments of the left clavicle (*lig. conoideum*).

Specific observations: *tuberculum conoideum* is extremely prominent (!) on the left side.

No paleopathological changes were noticed in the child individual.

Grave 16

The grave contained skeletal remains of a male, adult individual aged around 25,⁵⁹ a female (?) juvenile individual, aged between 16–20,⁶⁰ and a child individual, of unknown sex aged 3 (Fig. 6; Plate I; Tables 1, 2, 3, 7 and 8).⁶¹

Paleopathological changes noticed in the adult individual are syphilis (*caries sicca*) on the frontal bone (Plate I/1 and 2),⁶² injuries accompanied by a subperiosteal hematoma and the infection of both tibiae (on the anterior side) and the left fibula (Plate I/5 and 6), osteoarthritis (on the ends of both humeri, on the upper ends of ulnas, on tuberositas of both tibiae and on the left talus) and traces of Schmorl's defect on two lumbar vertebrae.

Markers of occupational stress in the form of hypertrophy (cortical defect) were present on the muscle attachment points of both scapulas (*m. pectoralis minor*, *m. biceps brachii* – *Caput longum*, *m. biceps brachii* – *Caput breve*, *m. triceps brachii* – *Caput longum*, *m. infraspinatus*, *m. subscularis*, *m. teres minor*, *m. teres major*), right clavicle (*m. trapezius*, *m. deltoideus*, *m. pectoralis major*, *m. sternocleidomastoideus*, *m. subclavius*), manubrium (*m. pectoralis major*), left ulna (*m. extensor pollicis brevis*, *m. abductor pollicis longus*, *m. supinator*, *m. brachialis*, *m. pronator teres*, *m. flexor digitorum superficialis*, *m. triceps brachii*), left radius (*m. pronator teres*, *m. extensor pollicis brevis*, *m. abductor pollicis longus*, *m. biceps brachii*; all attachment points on the lower end on the posterior side), right and left humerus (all attachment points), right and left femur (*m. iliopsoas*, *m. vastus lateralis*, *m. adductor magnus*; all attachment points on the posterior side (except on the left femur *gastrocnemius* – *Caput mediale* because that part of bone is missing and nothing can be claimed with certainty)). Markers of occupational stress in the form of hypertrophy (cortical defect) were present on the ligament attachment points of the right clavicle (*lig. trapezoideum*, *lig. conoideum*, *lig. costoclaviculare*). Manubrium is asymmetric (as if the right side of the body was laterally stretched and shortened)

⁵⁶ Degree of bone preservation: II category (a well preserved incomplete cranial and postcranial skeleton).

⁵⁷ Degree of bone preservation: II category (a well preserved incomplete cranial and postcranial skeleton).

⁵⁸ Degree of bone preservation: II category (a well preserved incomplete cranial and postcranial skeleton).

⁵⁹ Degree of bone preservation: II category (a well preserved incomplete cranial and postcranial skeleton).

⁶⁰ Degree of bone preservation: II category (a well preserved incomplete cranial and postcranial skeleton).

⁶¹ Degree of bone preservation: II category (a well preserved incomplete cranial and postcranial skeleton).

⁶² This is the first material confirmation of the appearance of syphilis in *Sirmium* between 1st–16th century.

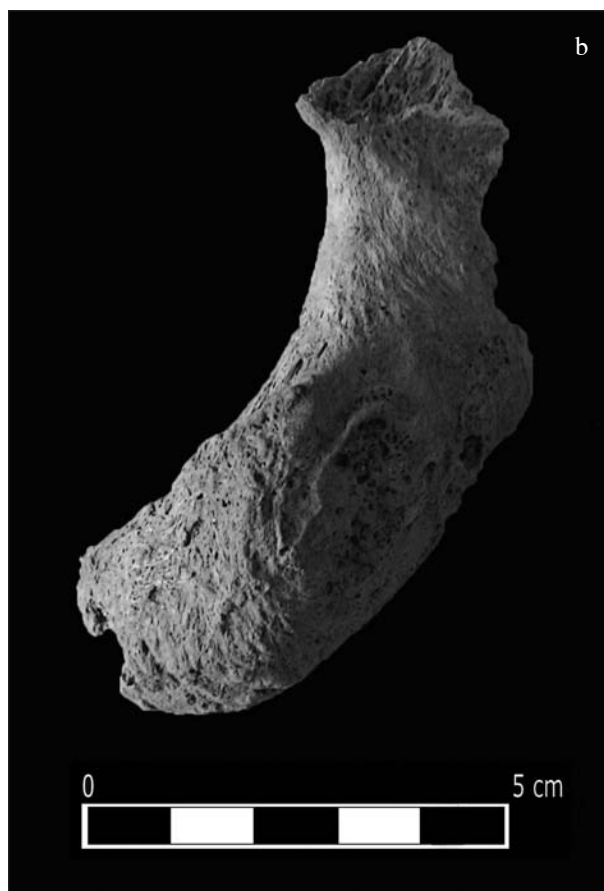

Fig. 14. Grave 17: infectious osteomyelitis:
a) on the left femur; b) on the fragment of innominate bone

Сл. 14. Гроб 17: инфективни остеомијелитис:
а) на левом фемуру; б) на фрагменту карличне кости

(Plate I/3). Olecranon of the left ulna was slightly separated. Two so-called „squatting facets“ were noticed on the left tibia (Plate I/4).

Epigenetic characteristics noticed on *norma frontalis* are openings and notches in the supraorbital region, and *linea nuchae suprema* (very prominent) on *norma occipitalis*. *Trochanter tertius* on both femurs is the only epigenetic characteristic on the postcranial part of the skeleton.

Osteoarthritis on calcaneus's *tuber calcanei* is a paleopathological change noticed in the juvenile individual.

No paleopathological changes were noticed in the child individual.

Grave 17

This grave contained skeletal remains of a male, adult individual aged around 65 (Figs. 6, 15a and 15b; Tables 1, 3 and 7).⁶³

Perceived paleopathological changes are irregularly fused fissures (or a fracture?) of left scapula's *angulus inferior*, left ulna (lower half of the body) and left radius (lower half of the body); osteoarthritis (on vertebrae, ribs, pelvic bones and ends of the left humerus, left ulna and left radius), traces of Schmorl's defect (on a preserved fragment of a vertebra), osteoporosis (on a preserved fragment of a vertebra and on innominate bones) and infective osteomyelitis (ischiatric parts of innominate bones and on the upper end of the left femur) (Figs. 15a and 15b).

Markers of occupational stress in the form of hypertrophy (cortical defect) were present on the muscle

⁶³ Degree of bone preservation: II category (a well preserved incomplete postcranial skeleton).

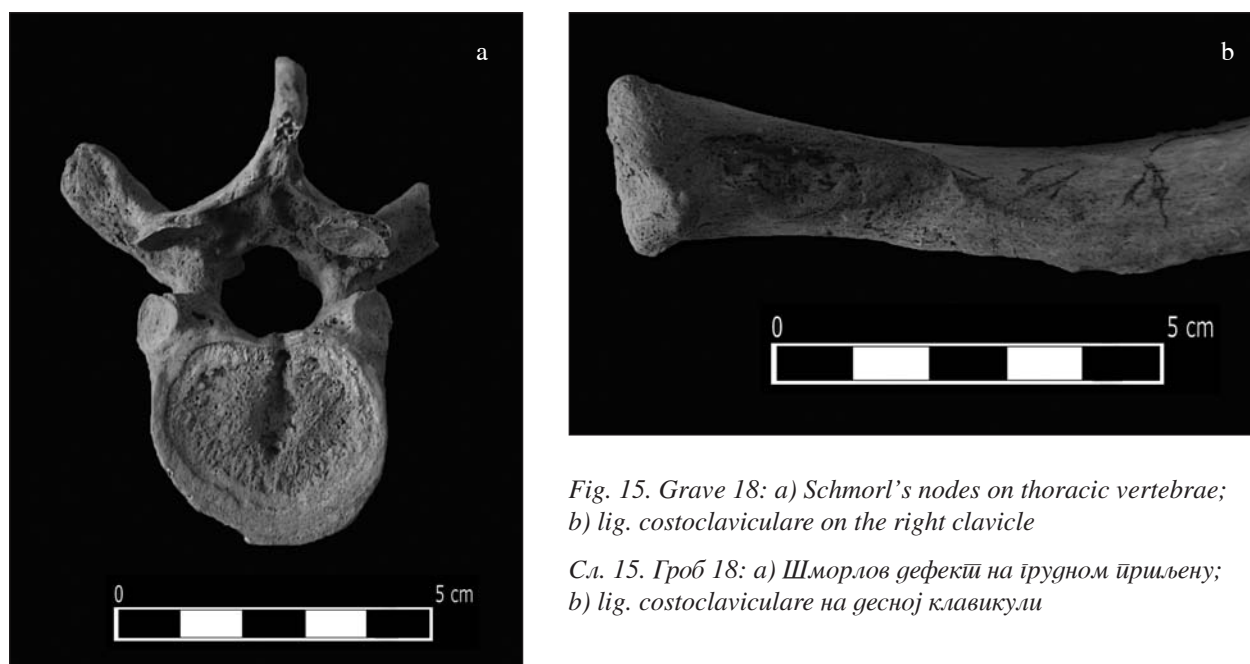

Fig. 15. Grave 18: a) Schmorl's nodes on thoracic vertebrae; b) lig. costoclaviculare on the right clavicle

Сл. 15. Гроб 18: а) Шморлов дефекти на грудном пршљену; б) lig. costoclaviculare на десној клавикули

attachment points of ribs (*Mm. levatores costarum*), left ulna (all attachment points except *m. triceps brachii mediale* because that part of bone is missing and could not be observed), left radius (all muscle attachment points) and the left humerus (*m. latissimus dorsi*, *m. pectoralis major*, *m. teres major*, *m. deltoideus*, *m. coracobrachialis*, *m. brachialis*, *m. flexor carpi ulnaris*, *m. anconeus*, *m. brachioradialis*, *m. extensor carpi radialis longus*, *m. extensor carpi radialis brevis*, *m. extensor digitorum*, *m. extensor digiti minimi*, *m. extensor carpi ulnaris*, *m. supinator*, *m. pronator teres*, *m. flexor carpi radialis*, *m. palmaris longus*, *m. flexor digitorum superficialis*, *m. triceps brachii – Caput laterale*, *m. triceps brachii – Caput mediale*).

Trochanter tertius on the left femur is the only perceived epigenetic characteristic.

Grave 18

The grave contained skeletal remains of a male, adult individual, aged between 35–45 (Figs. 6, 15a and 15b; Tables 1 and 6).⁶⁴

Perceived paleopathological changes were fused rib fissures, *spondylarthrosis* (II–III degree) on L4, osteoarthritis on T8–T12 and traces of Schmorl's defect on T8–T12 and L1–L3 (measuring from 0.5 x 0.5 cm to 0.5 x 2 cm) (Fig. 15a).

Markers of occupational stress in the form of hypertrophy (cortical defect) were visible on the muscle attachment points of the left scapula (*m. infraspinatus*,

m. subscularis, *m. teres minor*, *m. teres major*), right clavicle (*m. trapezius*, *m. deltoideus*, *m. pectoralis major*, *m. sternocleidomastoideus*, *m. subclavius*), 12 ribs (*Mm. levatores costarum*), left ulna (*m. supinator*, *m. brachialis*, *m. pronator teres*, *m. flexor digitorum superficialis*, *m. triceps brachii*), left radius (*m. biceps brachii*), right humerus (*m. supraspinatus*, *m. subscapularis*, *m. latissimus dorsi*, *m. pectoralis major*, *m. teres major*, *m. infraspinatus*, *m. teres minor*) and left humerus (*m. flexor carpi ulnaris*, *m. anconeus*, *m. brachioradialis*, *m. extensor carpi radialis longus*, *m. extensor carpi radialis brevis*, *m. extensor digitorum*, *m. extensor digiti minimi*, *m. extensor carpi ulnaris*, *m. supinator*, *m. pronator teres*, *m. flexor carpi radialis*, *m. palmaris longus*, *m. flexor digitorum superficialis*).

Markers of occupational stress in the form of hypertrophy (cortical defect) were visible on the ligament attachment points of the right clavicle (*lig. trapezoideum*, *lig. conoideum*, *lig. costoclaviculare*) (Fig. 15b).

Dislocated bones I

The bones belong to a male, adult individual, aged between 55–65 (Tables 1 and 7).⁶⁵

⁶⁴ Degree of bone preservation: II category (a well preserved incomplete postcranial skeleton).

⁶⁵ Degree of bone preservation: II category (a well preserved incomplete postcranial skeleton).

No paleopathological changes were noticed.

Markers of occupational stress in the form of hypertrophy (cortical defect) were visible on the muscle attachment points of the right humerus (*m. pectoralis major*; *m. latissimus dorsi*; *m. teres major*; *m. deltoideus*,

m. coracobrachialis, *m. brachioradialis*, *m. extensor carpi radialis longus*, *m. extensor carpi radialis brevis*, *m. pronator teres*, *m. flexor carpi radialis*, *m. palmaris longus*, *m. flexor carpi ulnaris*, *m. flexor digitorum superficialis*).

Table 1. Sex and age structure of individuals buried on east part of the Site No. 37

Табела 1. Полна и старосна структура индивидуа сахрањених на источном делу локалитета 37

INDIVIDUAL AGE		MALE	FEMALE	UNDETERMINED SEX	TOTAL
INFANS I	fetus	-	-	-	-
	NB – 0,5 years	-	-	-	-
	0,5 – 1 years	-	-	-	-
	1,5 – 2 years	-	2	-	2
	2,5 – 3 years	2	1	2	5
	3,5 – 4 years	-	-	1	1
	4,5 – 5 years	1	-	-	1
	5,5 – 6 years	-	-	-	-
	6,5 – 7 years	-	-	-	-
INFANS II	7,5 – 8 years	-	-	-	-
	8,5 – 9 years	-	-	-	-
	9,5 – 10 years	-	-	-	-
	10,5 – 11 years	-	-	-	-
	11,5 – 12 years	-	-	-	-
	12,5 – 13 years	-	-	-	-
	13,5 – 14,5 years	-	-	-	-
UNKNOWN AGE	-	-	4	4	
TOTAL NUMBER OF CHILDREN	3	3	7	13	
JUVENILIS I (15-18 years)	-	1	1	2	
JUVENILIS II (19-22 years)	1	-	1	1	
ADULTUS I (23-30 years)	3	-	-	3	
ADULTUS II (31-40 years)	1	1	-	2	
MATURUS I (41-50 years)	-	-	-	-	
MATURUS II (51-60 years)	1	-	-	1	
SENILIS I (61-70 years)	1	-	-	1	
SENILIS II (71 and more)	-	-	-	-	
UNKNOWN AGE	2	-	3	5	
TOTAL NUMBER OF JUVENILES AND ADULTS	10	3	4	16	
TOTAL NUMBER OF INDIVIDUALS	13	6	11	29	

STATURE (CM)	GRAVE 1	GRAVE 2 (I)	GRAVE 2 (II)	GRAVE 4	GRAVE 5 (I)	GRAVE 8 (I)	GRAVE 11	GRAVE 16 (III)
HUMERUS	76	96	-	-	-	87	86	-
RADIUS	75	94	87	-	79	87	-	91
ULNA	-	-	-	91	76	86	86	-
FEMUR	75	93	-	-	77	88	-	-
TIBIA	-	91	-	-	77	-	-	-
FIBULA	-	92	-	-	77	-	-	-
MEDIUM	75	93	87	91	77	87	86	91

Table 2. Stature of children

Табела 2. Телесна висина децијих индивида

STATURE (CM)	GRAVE 12	GRAVE 13	GRAVE 16 (I)	GRAVE 17	DISLOCATED BONES II (I)
HUMERUS	165 ± 4	168 ± 5	176 ± 5	168 ± 5	-
RADIUS	167 ± 4	170 ± 5	170 ± 5	174 ± 5	-
ULNA	167 ± 4	171 ± 5	172 ± 5	-	-
FEMUR	163 ± 4	-	-	-	-
TIBIA	-	169 ± 4	181 ± 4	-	147 ± 4
FIBULA	166 ± 4	169 ± 4	-	-	-
MEDIUM	166 ± 4	169 ± 5	175 ± 5	171 ± 5	147 ± 4

Table 3. Stature of juveniles and adults

Табела 3. Телесна висина јувенилних и одраслих индивида

Dislocated bones II

The bones belong to a female, juvenile individual, aged around 18, and a child, of unknown sex and age (Tables 1, 3 and 8).⁶⁶

Perceived paleopathological changes in the juvenile individual are fusion of the right tibia and right fibula (exophytes merging with the right fibula are noticed on the right tibia, which is unfortunately not preserved in material) and the disorder in the right knee joint formation.

Markers of occupational stress in the form of hypertrophy (cortical defect) were visible on the muscle attachment points of the right femur (*m. gluteus maxi-*

mus, m. pectineus, m. adductor brevis, m. vastus lateralis, m. adductor magnus, m. vastus medialis, m. vastus intermedius, m. adductor longus, m. biceps femoris – Caput breve, m. gastrocnemius – Caput mediale, m. adductor magnus, m. plantaris, m. gastrocnemius – Caput laterale, m. popliteus) and in the form of „squatting facets“ on the right tibia (2).

No paleopathological changes were noticed in the child.

⁶⁶ Degree of bone preservation: II category (a well preserved incomplete postcranial skeleton).

CRANIAL SKELETON	GRAVE 12	GRAVE 13
Primary cranial measures		
<i>Cranial Index</i>	84.27 brachycranic	92.39 ultra brachycranic
<i>Mean Porion–Height Index</i>	71.95 medium	73.86 high
<i>Fronto–Parietal Index</i>	62.67 stenometopic	59.49 stenometopic

Table 4. Indices on the cranial skeleton

Табела 4. Индекси на кранијалном скелету

CRANIAL SKELETON	GRAVE 12	GRAVE 13	GRAVE 15 (I)	DISLOCATED BONES IV
The Orbits				
<i>Orbital Index</i>	- 86.04 mesoconchy	- -	- -	- -
Mandible				
<i>Mandibular Index</i>	85.83	-	-	-
<i>Mandibular Robustness Index</i>	43.63	30	40.62	32.14
<i>Mandibular Branch Index</i>	47.54	47.37	-	46.87
<i>Fronto–mandibular Index</i>	95.43 mesomandibular	-	-	-

Table 5. Indices on the cranial skeleton

Табела 5. Индекси на кранијалном скелету

POSTCRANIAL SKELETON	GRAVE 12	GRAVE 13	GRAVE 18
Sacrum			
<i>Sacral Index</i>	-	100.44	-
Clavicle			
<i>Clavicolohumeral Index</i>	- 44.69	- -	- -
<i>Robustness Index</i>	- 23.08	- -	32.13 -

Table 6. Indices on the postcranial skeleton

Табела 6. Индекси на посткранијалном скелету

POSTCRANIAL SKELETON	GRAVE 12	GRAVE 13	GRAVE 16 (I)	GRAVE 17	DISLOCA-TED BONES I	DISLOCATED BONES IV
Humerus						
<i>Robusticity Index</i>	- 17.81	- 19.23	18.53 18.39	- 21.93	- -	- -
<i>Cross–Section Index</i>	80.95 85	- 85.71	80.43 84.44	- 78	76 -	77.78 -
<i>Radiohumeral Index</i>	- 72.81	- 75.32	- 71.22	- 80.32	- -	- -
Radius						
<i>The Length–Thickness Index</i>	16.16 16.22	19.96 19.11	- 16.95	- 18.72	- -	- -
<i>Cross–Section Index</i>	4.8 4.95	5.54 5.78	- 5.43	- 5.95	- -	- -
<i>The Length–Breadth Index</i>	13.54 13.23	15.08 14	- 14.34	- 16.17	- -	- -
Ulna						
<i>Caliber Index</i>	15.35 -	16.74 -	- 16.52	- 16.95	- -	- -

Table 7. Indices on the postcranial skeleton

Табела 7. Индекси на постранијалном скелету

POSTCRANIAL SKELETON	GRAVE 10	GRAVE 12	GRAVE 13	GRAVE 16 (I)	DISLOCATED BONES (II) I
Femur					
<i>Robusticity Index</i>	- -	- 12.41	- -	13.49 13.64	- -
<i>Pilastric Index</i>	- -	98.21 107.69	116.98 109.09	108.63 107.61	94.34 -
<i>Platymeric Index</i>	- -	77.27 platymeric 75.38 platymeric	84.37 platymeric 87.09 eurymeric	97.57 eurymeric 91.77 eurymeric	96.87 eurymeric -
Tibia					
<i>The Length–Breadth Index</i>	- -	- -	21.39 20.83	- 18.54	22.03 -
<i>Platynemic Index</i>	79.41 eurycn. 69.44 mesocn.	71.67 eurycn. 66.13 mesocn.	67.65 mesocn. 65.71 mesocn.	74.28 eurycn. 69.01 mesocn.	81.82 eurycn. -
Fibula					
<i>The Length–Breadth Index</i>	- -	8.82 8.45	9.17 9.72	- -	- -

Table 8. Indices on the postcranial skeleton

Табела 8. Индекси на постранијалном скелету

Dislocated bones III

The bones belong to a male (?) adult individual, of unknown age (Table 1).⁶⁷

No paleopathological changes were noticed.

Dislocated bones IV

The bones belong to a male, adult individual, aged between 25–30 (Tables 1, 5 and 7).⁶⁸

Osteoarthritis on the glenoid cavity of the right scapula is the only perceived paleopathological change.

Teeth analysis showed the presence of the following teeth: 14, 16 (root), 17, 18, 23, 24, 25, 43, 44 and 48. Teeth 11, 12, 13, 21, 22, 26, 31, 32, 33, 34, 35, 41 and 42 were lost postmortem, and teeth 15, 45, 46 and 47 antemortem. Abrasion of the 1st degree (in enamel) was noted on teeth: 14 (→II) and 17, 2nd degree (exposed dentin) on 24, 25, 43 and 44, and 3rd degree (to the bottom of fissures) on teeth 23 and 48. Periodontal disease and hypoplasia were moderately prominent. A cyst was noticed, 1 cm in diameter, on the buccal side of tooth 16. Teeth rotation is the only anomaly related to jaws and dental arch. Caries was noticed in teeth: 14 (distal carious spot 0.3 cm in length), 16 (so-called gross-gross caries) 17 (mesial, caries 0.4 cm in diameter), 18 (occlusal, caries shaped as a dot) and 48 (occlusal, three caries shaped as a dot; mesial caries 0.4 cm in diameter). No calculus was noticed. Occlusion could not be determined.

A noticeable epigenetic characteristic on *norma frontalis* is *sulci frontales* (one on the left side), and *os fonticuli posterolateralis* on *norma lateralis* (one on the right side, 0.7 x 1 cm in size, and one on the left side, measuring 0.85 x 0.5 cm).

DISCUSSION AND CONCLUSION

Paleodemographic structure of the site

Anthropological analysis revealed that on the eastern part of Site No. 37, the total of 29 individual were buried: 16 adults (55.2%) and 13 children (44.8%) (Table 1).

The average life expectancy of individuals was, relatively speaking, 20 years, and regarding adult individuals only, 34 years. The average life expectancy of males was 38, and women 25 years. It is an interesting fact that the highest mortality of children was between ages 1.5 to 5 (69%).⁶⁹

Average stature of adult females was 157 ± 4 cm, and males 172 ± 5 cm.

Paleopathological finds

Due to the nature and types of the most prevalent diseases, and relating different immunity levels individuals displayed, paleopathological changes in children and adults encountered in the described osteological material, were observed separately.

Children

Diseases which left a direct mark on osteological material of children were caused by blood disorders (anemia, porotic hyperostosis (23%), *cribra orbitalia* (15%), *cribra femora* (30%)) and lesions near ends of long postcranial bones (15%), skeleton development anomalies (dysplasias) (8%), middle ear inflammation (23%) and infective bone inflammations (tuberculosis) (15%).⁷⁰

However, most of these diseases could not have been the single direct cause of death in children. The highest mortality in children happened after the first year of age. Concerning children older than age one, it can be concluded that even though nutritious needs had decreased especially after age three, diet had still played an important role. Likewise, diarrhea, respiratory and gastrointestinal infections were still the major cause of death, together with accidental deaths, which played a significant role as well.

Adults

When it comes to adult individuals buried at the Site No. 37 the situation is somewhat different. Traces of a much larger number of diseases is visible in the osteological material belonging to these individuals:⁷¹ injuries, fissures and fractures (25%), abnormalities in skeleton development (fusion) (6%), joint diseases (50%), Schmorl's defect (25%), metabolic diseases (6%), changes in bone caused by blood disorders (13%), changes in bone caused by circulation disorders (13%), bone tumors (13%) and infectious bone inflammations (6%).⁷²

Mortality in adults during 10th–12th century could have been the consequence of many diseases. Likewise,

⁶⁷ Degree of bone preservation: II category (a well preserved incomplete postcranial skeleton).

⁶⁸ Degree of bone preservation: II category (a well preserved incomplete cranial and postcranial skeleton).

⁶⁹ cf. Miladinović-Radmilović 2011, 514, 559–564.

⁷⁰ cf. Miladinović-Radmilović 2011, 516, 565, 566.

⁷¹ cf. Miladinović-Radmilović 2011, 516, 517, 566–571.

⁷² Syphilis existed in Europe in ancient times. However, written confirmation of this disease in this region dates from 1495 (Bala and Hegeš 1994, 230).

poor sanitation, respiratory and gastrointestinal infections, various poisonings (“St. Anthony’s fire” *Ignis sacer*, *Pestis igne*), and epidemics (typhus (*Typhus exanthematicus*), dysentery (*Dysentaria*), smallpox (*Morbilli*), scarlet fever (*Scarlatina*), variola (*Variola vera*), famine (*Hunger typhus*), diphtheria or croup (*Morbus aegyptiacus* or *Ulcera syriaca*)), as well as plague, leprosy could have been a major cause of mortality.

Dental analysis

Dental analysis pointed out the occurrence of abrasion, hypoplasia, periodontal disease, calculus, cysts, anomalies of the jaw and dental arch, and the significant presence of caries on teeth of these individuals. It ranged from caries stains, dot-shaped caries, developed caries, so-called “gross-gross” caries, to caries that resulted in teeth loss.

Markers of occupational stress

Markers of occupational stress were noticed in clavicles, scapulas, sternums, humeruses, radiuses, ulnas,

femurs, tibias and fibulas. Occupational stress markers are indicators of activities an individual engaged in during their lifetime. Certainly, they are not enough to determine precisely what activity that was, but it can be concluded which body parts were most exposed to stress (muscle and ligament attachment points, so-called „squatting facets“ etc.) (50%).⁷³

* * *

Finally, the importance of the anthropological and archaeological analysis of the Belo Brdo populations from these parts should be emphasized once more. That way we would not only reconstruct and interpret the lifestyle, social conditions, types and sources of food and health status of these ancient people, but also create the whole picture about the people’s quality of living during a period, that in these parts, lasted for two centuries at least.

Translated by Dragan Marjanović

⁷³ cf. Miladinović-Radmilović 2011, 517, 571, 572.

BIBLIOGRAPHY:

Бала и Хегеш 1994 – Ф. Бала и А. Хегеш, Медицина и здравствена култура на тлу данашње Војводине од IX до XVI века. Стр. 155–238 у *Историја медицине и здравствене културе на тлу данашње Војводине*, том I, ур. Б. Берић. Нови Сад: Матица Српска, Српска академија наука и уметности – огранак у Новом Саду.

Bass 1995 – W. M. Bass, *Human Osteology, A Laboratory and Field Manual*. Columbia: Missouri Archaeological Society.

Bedić i Novak 2010 – Ž. Bedić i M. Novak, Stenjevci – Prikaz kvalitete i uvjeta života Bjelobrske populacije na temelju bioarheološke analize. *VAMZ*, 3.s., XLIII 41–57.

Brothwell 1981 – D. R. Brothwell, *Digging up bones*. London: British Museum (Natural History) and Oxford: Oxford University Press, 1981.

Buikstra and Ubelaker 1994 – J. E., Buikstra and D. H., Ubelaker, *Standards for data collection from human skeletal remains*. Arkansas Archeological Survey Research Series, No 44. Fayetteville, Arkansas: Arkansas Archeological Survey 1994.

Ђурић-Срејић 1995 – М. Ђурић-Срејић, *Увод у физичку антропологију древних популација*. Београд: Завод за уџбенике и наставна средства.

Ferembach, Schwidetzky and Stloukal 1980 – D. Ferembach, I. Schwidetzky and M. Stloukal, Recommendations for age and sex diagnosis of skeletons. *Journal of Human Evolution* 7: 517–549.

Garn, Lewis and Kerewsky 1965 – S. Garn, A. Lewis and R. Kerewsky, X – linked inheritance of teeth size. *Journal of Dental Research* 44: 439–441.

Hauser and De Stefano 1989 – G. Hauser and G. F. De Stefano, *Epigenetic Variants of Human Skull*. Stuttgart: E. Schweizerbart'sche Verlagsbuchhandlung, 1989.

Hillson 1990 – S. Hillson, *Teeth*. Cambridge: Cambridge University Press.

Hillson 1996 – S. Hillson, *Dental Anthropology*. Cambridge: Cambridge University Press.

Işcan, Loth and Wright 1984a – M. Y. Işcan, S. R. Loth and R. K. Wright, Metamorphosis at the sternal rib end: A new method to estimate age at death in males. *American Journal of Physical Anthropology* 65: 147–156.

Işcan, Loth and Wright 1984b – M. Y. Işcan, S. R. Loth and R. K. Wright, Age estimation from the rib by phase analysis: White males. *Journal of Forensic Sciences* 29: 1094–1104.

Işcan, Loth and Wright 1985 – M. Y. Işcan, S. R. Loth and R. K. Wright, Age estimation from the rib by phase analysis: White females. *Journal of Forensic Sciences* 30: 853–863.

Lovejoy 1985 – C. O. Lovejoy, Dental Wear in the Libben Population: Its Functional Patterns and Role in the Determination of Adult Skeletal Age at Death. *American Journal of Physical Anthropology* 68: 47–56.

Lovejoy et al. 1985 – C. O. Lovejoy et al., Chronological matamorphosis of the auricular surface of the ilium: A new method for the determination of skeletal age at death. *American Journal of Physical Anthropology* 68: 15–28.

Mikić 1978 – Ž. Mikić, O antropološkoj metodologiji terenske obrade skeletnih nalaza. *Godišnjak Centra za balkanološka ispitivanja ANUBiH* 16/14: 3–44 (201–242).

Miladinović-Radmilović 2011 – N. Miladinović-Radmilović, *Sirmium – Necropolis*. Beograd: Arheološki institut, Sremska Mitrovica: Blago Sirmijuma.

Милошевић 1994 – П. Милошевић, *Топографија Сирмијума*. Археолошка грађа Србије I/3. Грађа за археолошку карту Војводине I. Нови Сад: Српска академија наука и уметности, огранак у Новом Саду.

Scheuer and Black 2000 – L. Scheuer and S. Black, *Developmental Juvenile Osteology*. London: Academic Press.

Schutkowski 1993 – H. Schutkowski, Sex Determination of Infant and Juvenile Skeletons: I. Morphognostic Features. *American Journal of Physical Anthropology* 90: 199–205.

Todd 1920 – T. W. Todd, Age changes in the pubic bone: I The male white pubis. *American Journal of Physical Anthropology* 3: 285–334.

Todd 1921a – T. W. Todd, Age changes in the pubic bone: II The pubis of the male Negro–white hybrid; III The pubis of the white female; IV The pubis of the female Negro–white hybrid. *American Journal of Physical Anthropology* 4: 1–70.

Todd 1921b – T. W. Todd, Age changes in the pubic bone: VI The interpretation of variations in the symphyseal area. *American Journal of Physical Anthropology* 4: 407–424.

Tomičić 2010 – Ž. Tomičić, Spoznaje o arheološkom nasleđu ranosrednjovekovnog groblja na položaju Bagruša kraj Petoševaca. *Archaeologia Adriatica* IV: 117–166.

Trotter and Gleser 1952 – M. Trotter and G. C. Gleser, Estimation of stature from long bones of American

whites and Negroes, *American Journal of Physical Anthropology* 10: 463–514.

Vallois 1937 – H. W. Vallois, La Durre de la vie chez l'Homme fossile. *L'Anthropologie* 47: 499–532.

Vodanović, Brkić, Demo i Šlaus 2003 – M. Vodanović, H. Brkić, Ž. Demo i M. Šlaus, Dentalne bolesti i način prehrane u ranosrednjovjekovnoj populaciji iz Bijelog Brda u Istočnoj Slavoniji u Hrvatskoj. *Acta Stomatol Croat*, Vol. 37, br. 3, 386.

Vodanović, Brkić i Demo 2004 – M. Vodanović, H. Brkić i Ž. Demo, Paleostomatološka analiza humanog kraniofacijalnoga osteološkoga materijala sa srednjovjekovnog nalazišta Bijelo Brdo kraj Osijeka. *VAMZ*, 3.s., XXXVII 251–261.

Walker and Pérez-Pérez – P. L. Walker and A. Pérez-Pérez, *Age, Height and Long Bone Growth in Children*. Unpublished manuscript.

Резиме: НАТАША МИЛАДИНОВИЋ-РАДМИЛОВИЋ, Археолошки институт, Београд

АНАЛИЗА ХУМАНОГ ОСТЕОЛОШКОГ МАТЕРИЈАЛА СА ИСТОЧНОГ ДЕЛА ЛОКАЛИТЕТА 37 У СРЕМСКОЈ МИТРОВИЦИ

Кључне речи. – средњовековни Сирмијум, Белобрдска култура, сифилис.

Локалитет 37 се налази на углу улица Вука Караџића и Светог Саве, на простору срушеног Градског затвора у Сремској Митровици. Заштитна археолошка ископавања извршена су 1968. и 1969. године на површини од 1600 m² (сл. 1 и 2). Том приликом истражени су део северног крила царске палате Сирмијума из IV века, гепидски културни слој из V века и део средњовековне некрополе са скелетним сахрањивањем из X–XII века. Налази са ове некрополе припадају Белобрдској култури. Остеолошки материјал хуманог порекла са овог локалитета је још седамдесетих година прошлог века послат у САД на антрополошку експертизу. Нажалост, резултати тих анализа до данас нису достављени Музеју Срема у Сремској Митровици и Археолошком институту у Београду. Такође, колико је аутору овог текста познато, они нису нигде ни публиковани.

У периоду од 1957. до 2007. године у Сремској Митровици су пронађени гробови са материјалом белобрдске културе X–XII века на укупно 11 локалитета (сл. 1 и 2). У питању су локалитети 4, 25, 34, 35, 37, 66, 83, 85, Јужни бедем, Мачванска Митровица и локалитет Траса канализације – Доситејева улица. За антрополошку анализу, нажалост, било је доступно само 82 скелета (са локалитета 83 – девет индивидуа, 85–65 индивидуа, Јужни бедем – две индивидуе, Мачванска Митровица – пет индивидуа, и са локалитета Траса канализације – Доситејева улица – једна индивидуа).

У септембру 2010. године екипа Завода за заштиту споменика културе из Сремске Митровице предузела је заштитна археолошка истраживања у улици Светог Саве. Том приликом је отворена сонда димензија 4 x 4 m (сл. 3–6). Пронађено је 18 гробова и четири групе дислоцираних костију (укупно 29 скелета). Оријентација скелета била је углавном

југозапад–североисток. Покојници су били положени на леђа, са рукама постављеним поред тела. Пронађен је и већи број гвоздених ексера, који је археологе навео на закључак да су покојници били смештени у дрвеним ковчезима.

Остеолошки материјал хуманог порекла са претходних ископавања локалитета 37, као што је већ истакнуто, није био доступан за антрополошку анализу, тако да смо одлучили да представимо анализу свих 29 индивидуа (табеле 1–8; сл. 1–15b; табла I) и тиме допринесемо стварању опште слике о овој популацији.

Наравно, велику потешкоћу у антрополошкој реконструкцији и интерпретацији представљало је и широко археолошко – хронолошко датовање (период X–XII века), чему је допринео, између осталог, и велики број налаза откривених на некрополама који нису били, како се наглашава, хронолошки осетљиви, као и недовољно велики број откривених скелета. Због тога је било немогуће прецизније пратити унутрашњу динамику ове популационе групе, чак и онда када је локалитет, односно некропола била ископана већим делом или у целини, за разлику од колега у нашој околини који су се већ успешно упустили у овакве подухвате.

Антрополошка анализа је показала да је на источном делу локалитета 37 било сахрањено укупно 29 индивидуа, и то: 16 одраслих (55,2%) и 13 дечјих (44,8%) индивидуа (табела 1).

Просечан животни век индивидуа, условно речено, био је 20 година, а ако се посматрају само одрасле индивидуе, износио је 34 године. Просечан животни век мушких индивидуа био је 38 година, а женских 25 година. Занимљиво је да је највећа смртност деце била у узрасту од 1,5–5 година живота (69%).

Просечна телесна висина женских индивидуа износила је 157 ± 4 cm, а мушких 172 ± 5 cm (табела 2).

Због саме природе и врста обољења које се најчешће појављују, као и услед различите отпорности које индивидуе показују у односу на њих, посебно смо посматрали палеопатолошке промене на дечјим и одраслим индивидуама са којима смо се срели приликом анализе овде описаног остеошког материјала.

Болести које су директно оставиле траг на остеошкој материјалу дечјих индивидуа јесу промене на костима узроковане крвним поремећајима (анемија, порозна хиперостоза – 23%, *cribra orbitalia* – 15%, *cribra femora* – 30%, и лезије при окрајцима дугих костију посткранијалног скелета – 15%), анормалије у развоју скелета (дисплазије – 8%), упале средњег уха – 23%, и инфективна запаљења костију (туберкулоза – 15%).

Међутим, већина од ових болести самостално није могла да буде директан узрок смрти дечјих индивидуа. Највећи морталитет деце био је после прве године живота. Што се тиче морталитета деце старије од годину дана, може се констатовати да, иако су нутриционе потребе деце смањене, нарочито након треће године живота, исхрана и даље има значајну улогу. Такође, дијареја, респираторне и гастроинтестијалне инфекције и даље су главни узроци смрти, а значајно место заузима и смрт несрећним случајем.

Када су у питању одрасле индивидуе сахрањене на локалитету 37, ситуација је нешто другачија. На остеошкој материјалу ових индивидуа видљиви су трагови много већег броја обољења: повреде, фисуре и преломи костију (25%), анормалије у развоју скелета (фузије – 6%), болести зглобова (50%), Шморлов дефект (25%), метаболичке болести (6%), промене на костима узроковане крвним поремећајима (13%), промене на костима узроковане поремећајима у циркулацији (13%), тумори костију (13%) и инфективна запаљења костију (6%).

Смртност одраслих особа у периоду X–XII века могла је да буде последица више обољења. Такође, и лоши санитарни услови, респираторне и гастроинтестиналне инфекције, разна тровања („Огањ Светог Антуна“ – *Ignis sacer*, *Pestis ignea*), као и епидемије (пегавац – *Typhus exanthematicus*), срдобоља (*Dysenteria*), мале богиње (*Morbilli*), шарлах (*Scarlatina*), велике богиње (*Variola vera*), глад (*Hunger typhus*), дифтерија или гушобоља (*Morbus aegyptiacus* односно *Ulcera syriaca*), затим куга, лепра – могли су да буду један од главних узрока смртности становништва.

Дентална анализа нам је скренула пажњу на појаву абразије, хипоплазије, пародонтопатије, каменца, цисти, анормалија вилице и зубног низа, али и на значајно присуство каријеса на зубима ових индивидуа. Он се кретао од кариозних мрља, каријеса у виду тачке, развијеног каријеса, тзв. „gross-gross“ каријеса, до каријеса који су за последицу имали губитак зуба.

Маркери окупационог стреса уочени су на клавикулама, скапулама, стернумима, хумерусима, радијусима, улнама, фемурима, тибијама и фибулама. Маркери окупационог стреса су показатељи активности којима се одређена индивидуа бавила у току живота. Наравно, на основу њих се не може тачно прецизирати о којој се делатности ради, али се може констатовати који део тела је био највише изложен притиску (хватишта мишића, хватишта лигамената, тзв. „кљечеће фасете“ итд. – 50%).

* * *

На крају, требало би још једном истаћи важност антрополошке и археолошке анализе Белобрдских популација код нас. Тиме бисмо успели не само да реконструирамо и интерпретирамо начин живота тих древних популација, социјалне услове, врсту и изворе хране, здравствено стање, већ и да створимо целокупну слику о квалитету живота људи у једном периоду који је на нашем простору трајао најмање два века.




Plate I – Grave 16: 1 and 2) caries sicca; 3) asymmetry of manubrium; 4) so-called „squatting facets“ on the lower end of left tibia; 5 and 6) injuries on tibias and on the left fibula accompanied by subperiosteal hematoma

Табла I – Гроб 16: 1 и 2) caries sicca; 3) асиметрија манубриума; 4) шизв. „кличеће фасете“ на доњем крајку леве тибије; 5 и 6) повреде тибија и леве фибуле праћене субпериосталним хематомом