

DRAGANA VULOVIĆ, Institute of Archaeology, Belgrade
NATAŠA MILADINOVIĆ-RADMILOVIĆ, Institute of Archaeology, Belgrade
ILIJA MIKIĆ, Institute of Archaeology, Belgrade

A CASE OF *MYOSITIS OSSIFICANS TRAUMATICA* ON ONE SKELETON FROM VIMINACIUM

e-mail: dragana.vulovic@gmail.com

Abstract – The Roman city and military camp of Viminacium is situated between the villages of Stari Kostolac and Drmno, 12 kilometres north-east of Požarevac, close to the confluence of the Mlava and the Danube. During its history, it became the biggest urban settlement and the capital of the province of Upper Moesia (*Moesia Superior*), later First Moesia (*Moesia Prima*). In one of the necropolises of Viminacium, Pećine, in grave No. 5785, skeletal remains of a juvenile male individual were discovered. The burial took place in Late Antiquity. Anthropological analyses revealed a fracture of the right femur followed by *myositis ossificans traumatica*. The trauma to the bone can damage the overlying muscle and, occasionally, the muscle tissue will respond to the trauma by producing bone directly in the muscle tissue itself. This condition is known as *myositis ossificans traumatica* (post-traumatic *myositis ossificans* or *myositis ossificans circumscripta*) and is most likely to occur in response to trauma in young male individuals, and in the femoral (the quadriceps muscles) or humeral region (brachium muscles).

Key words – Viminacium, Late Antiquity, site of Pećine, *myositis ossificans traumatica*, bone fracture

The Roman city and military camp of *Viminacium* is situated between the villages of Stari Kostolac and Drmno, 12 kilometres north-east of Požarevac, close to the confluence of the Mlava and the Danube (Map 1). During its history, it became the biggest urban settlement and the capital of the province of Upper Moesia (*Moesia Superior*), later First Moesia (*Moesia Prima*). It represented one of the most important military strongholds, not only in Upper Moesia, but it also represented the area from which Roman legions operated in other provinces as well.

MATERIAL AND METHODS

In one of the necropolises of Viminacium, Pećine, in grave No. 5785, skeletal remains of a juvenile male in-

dividual were discovered. The burial took place in Late Antiquity. The deceased juvenile was laid on the back with hands clasped on his stomach. The deceased's skull was not found. The orientation of the grave was West–East (Fig. 1).

Standard anthropological analysis was conducted at the Institute of Archaeology in Belgrade. The analysis included the estimation of sex and age at the moment of death, paleopathological and dental analyses, and a macroscopic examination of entheses.

For sex determination on the skeletal material of this individual we adopted a combination of morphological and metrical methods. Specific attention was paid to morphological elements of the pelvis (*sulcus praeauricularis*, *incisura ischiadica s. ischialis major*,

This text is a result of the projects *Viminacium, Roman city and military legion camp – research of the material and non material culture of inhabitants by using the modern technologies of remote detection, geophysics, GIS, digitalisation and 3D visualisation* (No 47018), *Romanization, urbanization and transformation of urban centres of civil, military and residential character in Roman provinces on the territory of Serbia* (No. 177007) and *Urbanization and development processes in the medieval society* (No. 177021), funded by the Ministry of Education, Science and Technological Development of the Republic of Serbia. We express our gratitude to Mr M. Radmilović for the map of the site (Map 1) and for post-production of all illustrations (Plates I and II)

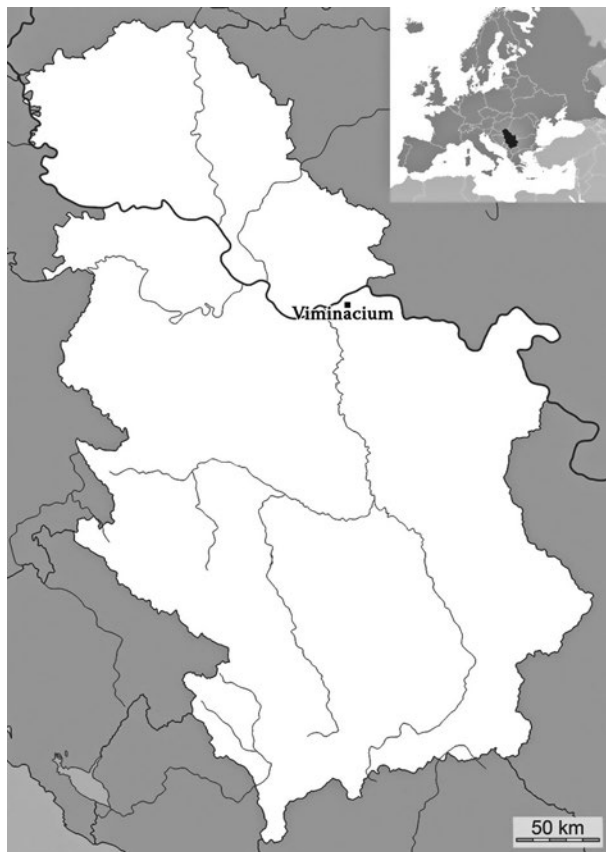


Fig. 1. Viminacium, site of Pećine, Grave 5785
(photo taken from Documentation Centre, Viminacium)

Сл. 1. Виминацијум, локалитет Пећине, гроб 5785
(фотографија је преузета из Документационог
центра Виминацијум)

Мапа 1. Локација Виминацијума на мапи,
са положајем Републике Србије у Европи
(мапу је нацртао М. Радмиловић)

Карта 1. Локација Виминацијума на карти,
са положајем Републике Србије у Европи
(карту је нацртао М. Радмиловић)

arc compose, the appearance of *os coxae*, *crista iliaca*, *fossa iliaca*), and the method of operation was adopted from a group of European anthropologists,¹ and Buikstra and Ubelaker.² Morphological and metric elements were observed during the analysis of other postcranial bones as well (Table 3). The morphological elements that caught our attention most were the degrees of development of: *tuberositas deltoideae*, *tuberositas radii* and *margo interosseus* (of the radius), *tuberositas ulnae* and *margo interosseus* (of the ulna), *linea aspera* and *tuberositas tibiae*. Bone appearance, body curvature and *facies auricularis* were morphological elements observed in the sacrum.³ Metric elements played a more significant role in sex determination based on the postcranial skeleton, and were given additional attention.

Individual age was established based on: degree of ossification of the epiphysis-diaphysis connections (table with time scales (in years) during which epiphysis-diaphysis connections ossify);⁴ morphological changes in sternal ends of ribs (metamorphoses of depth, joint cavities, shape, edges and ridge configuration were examined, together with overall state of bone, based on ten (0–8) phases of progression covering the

period from 18 to over 70 years);⁵ sacroiliac region (individual age of adult individuals was determined using models defined by Lovejoy and his associates; they classified the changes in this region in eight stages, from late adolescence to old age phase, with most attention directed to the observation of position, edge lipping and porosity of the bone in this region).⁶

Stature was calculated using Trotter and Gleser's formulas.⁷

RESULTS

The anthropological analysis revealed that in grave No. 5785 a juvenile male individual, aged 20–25 years (medium stature: 163 ± 4 cm, Tables 1 and 2), was buried.

¹ Ferembach *et al.* 1980, 519–527.

² Buikstra, Ubelaker 1994, 15–21.

³ Mikić 1978, 18, 19; Bass 1995, 114.

⁴ Ferembach *et al.* 1980, 531.

⁵ Işcan *et al.* 1984a; idem. 1984b; idem. 1985.

⁶ Lovejoy *et al.* 1985.

⁷ Trotter, Gleser 1952.

GRAVE 5785					
POSTCRANIAL SKELETON					
right humerus	-	P1/3	M1/3	D1/3	D.E.
left humerus	-	P1/3	M1/3	D1/3	2/3D.E.
right radius	P.E.	P1/3	M1/3	D1/3	-
left radius	P.E.	P1/3	M1/3	D1/3	-
right ulna	P.E.	P1/3	M1/3	-	-
left ulna	1/2P.E.	P1/3	M1/3	D1/3	-
right femur	P.E.	P1/3	M1/3	D1/3	D.E.
left femur	P.E.	P1/3	M1/3	D1/3	D.E.
right tibia	-	P1/3	M1/3	D1/3	dec.D.E.
left tibia	P.E.	P1/3	M1/3	D1/3	dec.D.E.
right fibula	-	P1/3	M1/3	D1/3	D.E.
left fibula	P.E.	P1/3	M1/3	1/2D1/3	-
33 bone fragm. of postcr. skeleton	0.4–4.5 cm in length				
right and left clavicle	both 75–100%				
manubrium	75%				
corpus sterni	100% dec.				
right and left scapula	25–50%				
sacrum	75%				
number of sacral vetrebrae	3 + 1/2				
promontorium	100%				
right iliac bone	100% dec.				
right ischium bone	75–100%				
right pubic bone	25–50%				
left iliac bone	100% dec.				
left ischium bone	75–100%				
left pubic bone	50–75%				
left patella	75%				
one cervical vertebra					
nine thoracic vertebrae, 10 body fragments and 12 fragment of processes of thoracic vertebrae					
one lumbal vertebra, one body fragment and three fragment of processes of lumbal vertebrae					
35 ribs fragments	3.05–14.1 cm in length				
I right <i>os metacarpale</i>	P.E.	P1/3	M1/3	D1/3	D.E.
I right <i>os metacarpale</i>	P.E.	P1/3	M1/3	D1/3	D.E.
III left <i>os metacarpale</i>	P.E.	P1/3	M1/3	-	-
a phalanx of hand	3				
right and left talus	both 100%				
right calcaneus	75–100%				
left calcaneus	100%				
right and left <i>os naviculare</i>	both 50%				
II right <i>os metatarsale</i>	P.E.	P1/3	M1/3	D1/3	D.E.
IV right <i>os metatarsale</i>	P.E.	P1/3	M1/3	D1/3	-
a phalanx of foot	1				

Table 1. List of preserved bones

Табела 1. Списак очуваних костију

Stature (cm) – calculation based on the length of	GRAVE 5785
Femur	162 ± 4
Tibia	163 ± 4
Fibula	163 ± 4
Medium stature	163 ± 4

Table 2. Stature

Табела 2. Телесна висина

The paleopathological analysis showed a healed fracture on the upper half of the body of the right femur (Plate I/1–4). It was most probably a spiral fracture, with anteversion (?), followed by *myositis ossificans traumatica* on the posterior side of the body, on the *linea aspera* (exostosis had spread to the medial side (Plate I/1–4)). Aside from the fracture, mild osteoarthritis was also noted on the tarsal bones, as well as *osteocondritis dissecans*, i.e., post-traumatic subarticular necrosis, with a diameter of 1.7 cm, on the medial condyle of the left femur (the mini-fracture is surrounded by a sclerotic repair zone, with the newly created formation in the centre (Plate I/5)). On the right scapula, a dislocation of the glenoid cavity can be seen, beneath the very cavity, above the *m. triceps brachii – Caput longum* (Plate II/4, 5). On the posterior part of the sacrum, a dislocation of one of the segments was noted (Plate I/6). On both iliac bones, a prominent sulcus above both the auricular surfaces was noted (Plate II/6, 7). On the left calcaneus, the *facies articularis talaris media* and *facies articularis talaris anterior* are separated, while they are merely doubled on the right one.

Very prominent muscular, ligamentous and tendinous entheses were visible: on both humeri (*m. deltoideus*, *m. pectoralis major*, *m. latissimus dorsi*, *m. teres major*, *m. biceps brachii – Caput longum*, *m. anconeus*, *m. extensor carpi radialis longus*, *m. extensor carpi radialis brevis*, *m. extensor digitorum*, *m. extensor digiti minimi*, *m. extensor carpi ulnaris*, *m. supinator* (Plate II/3)), on both ulnae (*m. supinator*, *m. brachialis* (only on the right ulna, the left one was damaged), *m. anconeus*, *m. flexor carpi ulnaris*, *m. triceps brachii* (on the right ulna)), on both radii (*m. biceps brachii*, *m. pronator teres*, *m. extensor digitorum*, *m. extensor indicis* (the right one), *m. extensor pollicis longus* (the right one)), on both clavicles (*lig. conoideum*, *m. subclavius*, *m. deltoideus* (only on the right one, the left one was damaged)), on two ribs (*Mm. levatores costarum*), on both scapulae (*m. triceps brachii – Caput*

longum), on both innominate bones (*ligg. sacroiliaca interossea*), and the right femur (prominent insertions at P1/3 and around the *linea aspera* (fracture), *m. iliopsoas*, *m. gluteus medius*), left femur (less prominent than those on the right one, the bone was damaged)), and on both femurs (*lig. cruciatum anterius*, *lig. cruciatum posterius*).

Also, lateral curvatures of the body can be noted on the ulnae, especially on the posterior side, in the upper part of the body (Plate II/1, 2).

DISCUSSION

Fracture/Trauma

The term fracture is used to describe any traumatic event that results in partial or complete discontinuity of a bone. Fractures can be traumatic or pathological, they can be closed or open, but also in the form of a complete or incomplete fracture (an incomplete fracture is when the break does not go through the entire bone; if the bone is broken entirely into separate segments, it is called a complete fracture).⁸ Traumatic fractures are most commonly caused by a strong direct or indirect force applied onto one or more bones, thus causing the bone to be broken, crushed or cracked. Pathological fractures are those caused by diseases (osteoporosis, bone tumours, etc.), and those caused by changes in bone tissue, which would have made them fragile and sensitive to the effects of minimal traumatic forces.⁹ Stress in bone results from the application of one or more of the following types of force: tension, compression, torsion or twisting, flexion or bending, and shearing.¹⁰

After the break, a phase of regeneration of the bone tissue begins, whose speed and success depends on the level of damage of the bone tissue and also the surrounding soft tissue, the place in which the bone was broken, whether the break occurred on a healthy or pathologically changed bone and whether it was a closed or an open fracture. Just one week later, in the place where the fracture occurred and around it, new bone tissue is formed (callus), which keeps growing in the following weeks and forms a thickening of the bone. The modelling of the structure of the callus comes later, because of the impact of static load.¹¹

⁸ Ђурић-Срејић 1995, 311; Ortner 2003, 120.

⁹ Ђурић-Срејић 1995, 311.

¹⁰ Ortner 2003, 120.

¹¹ Ђурић-Срејић 1995, 311.

POSTCRANIAL SKELETON (CM)	GRAVE 5785	POSTCRANIAL SKELETON (CM)	GRAVE 5785
CLAVICLE*		FEMUR*	
Circumference at middle of bone	4.20 4.10	Maximum length	41.60 43.00
SCAPULA*		Physiological length	41.20 42.70
Glenoid cavity length	4.25 -	Subtrochanteric anterior-posterior diameter	2.70 2.70
SACRUM		Subtrochanteric mediolateral diameter	3.70 3.60
Maximum anterior breadth	11	Anterior-posterior diameter of the midshaft	2.90 2.60
STERNUM		Mediolateral diameter of the midshaft	3.15 2.90
Manubrium height	5.5	Maximum diameter of the head	4.65 4.65
Corpus sterni length	9.5	Circumference of the midshaft	9.40 8.70
Corpus sterni breadth	3.9	Bicondylar width	- 7.75
Width of I sternebra	2.4	<i>Robusticity index</i>	15.53 14.75
Width of II sternebra	3	<i>Pilastric Index</i>	72.97 75.
HUMERUS*		<i>Platymeric index</i>	92.06 89.65
Maximum diameter midshaft	2.20 2.25	TIBIA*	
Minimum diameter midshaft	1.90 1.90	Maximum length	- 33.6
Least circumference of the shaft	6.40 6.30	Physiological length	- 32.6
Biepicondylar width	6.40 -	Anterior-posterior diameter at the nutrient foramen	3.50 3.40
Articular width	4.80 -	Mediolateral diameter at the nutrient foramen	2.40 2.15
<i>Cross section Index</i>	86.36 84.44	Circumference at the nutrient foramen	9.60 9.30
RADIUS*		Proximal breadth	- 7.50
Anterior-posterior diameter of the midshaft	1.20 1.20	Distal breadth	5.10 5.00
Mediolateral diameter of the midshaft	1.80 1.65	Least circumference of the shaft	7.60 7.50
Least circumference of the shaft	4.30 4.40	<i>The Length-Breadth Index</i>	- 22.32
ULNA*		<i>Platycnemic Index</i>	68.57 63.23
Least circumference of the shaft	- 3.9	FIBULA*	
Bones marked with * have two measurements, upper is for the right, and lower is for the left side of the body. * вредности су дате прво за десну, а потом и за леву страну		Maximum length	- 33.5
		Least circumference of the shaft	3.40 3.30
		<i>The Length-Width Index</i>	- 9.85

Table 3. Measurements and indices of postcranial skeleton

Табела 3. Мере и индекси на постранијалном скелету

Complications of fractures include: infection, tissue necrosis and loss of innervation, inadequate fusion of the fracture, bone deformity, traumatic arthritis, joint fusion, and *traumatic myositis ossificans*.¹²

Myositis ossificans traumatica

Evidence of trauma in archaeological populations is restricted to visible changes in the skeletal remains, unless, of course, soft tissue is preserved. Therefore, most of the soft-tissue injuries of archaeological populations remain invisible. Bone trauma can damage the overlying muscle, producing a hematoma, and *myositis ossificans traumatica* occurs as a response to that trauma.

Myositis ossificans (also called: *traumatic myositis ossificans*, heterotopic ossification, ectopic ossification, neurogenic ossifying fibromyopathy, reactive Mesenchymal proliferation, ossifying hematoma, or pseudomalignant osseous tumour of soft tissues) was first described by Guy Patin in 1692 and later named by Von Dusch, in 1868.¹³ It represents localised, non-neoplastic, reparative extra-osseous lesions that are comprised of reactive hypercellular fibrous tissue, cartilage, and/or bone in muscle or soft tissue.¹⁴ It usually represents one of the complications of fractures (as in this case), trauma (acute or chronic), a blunt injury that causes deep tissue bleeding, although it may also occur without any history of skeletal injuries.¹⁵ Repeated minor trauma – sometimes seen on the inside of the thighs of horseback riders – can also result in *myositis ossificans*. In modern populations' surgery, especially when it comes to hip replacements, sports injuries or accidents, people who have paraplegia can also develop *myositis ossificans*.

Myositis ossificans can be sub classified into four subtypes, according to Samuelson and Coleman:¹⁶ 1) *myositis ossificans progressiva* (usually starts soon after birth, which progressively affects all skeletal muscles, and leads to death), 2) *myositis ossificans traumatica* (is the more common form of the disease, and occur following, and probably as a result of, local trauma), 3) *myositis ossificans* associated with neuromuscular and chronic diseases (usually occurs in association with neuromuscular disorders, burns, chronic infection, or other systemic diseases), and 4) non traumatic *myositis ossificans* (occurring in those with no definitive causative factor).

Myositis ossificans traumatica is caused by the avulsion of tendons or muscle attachments, generating a hematoma. With time, the hematoma is usually dis-

solved. Occasionally, however, the muscle tissue will respond to the trauma by producing bone directly in the muscle tissue itself, often in association with the hematoma. The resulting calcified and often ossified mass of woven bone constitutes the lesion known as *myositis ossificans traumatica* (post-traumatic *myositis ossificans* or *myositis ossificans circumscripta*). This excessive formation of bone by muscle can be entirely separated from the bone or it can become part of the existing bone tissue.¹⁷ The most common areas are the extensors and adductors of the thigh and the deltoid and pectoralis muscles and their associated tendons.

These traumatic lesions are most commonly seen in active adolescents and young adults (as in this case, in a juvenile individual), younger than 30 (in their 20s) with a peak occurrence between 11–20 years (it is rare among children under 10 years old), participating in some physical activities (sports, especially among athletes), with a slight male predominance (gender ratio: M/F is 1.2/1 to 2.2/1).¹⁸ Frequency of occurrence: *myositis ossificans* accounts for < 1% of benign, soft tissue tumours.

Myositis ossificans traumatica can be seen relatively often in skeletons, usually manifested by the presence of irregularly shaped pieces of bone attached to long bones. Lesions manifest as painless or painful masses. Ossification may begin in first 7–10 days, bony

¹² Ortner 2003, 128.

¹³ Lungu 2011, 25; Meyers 2008, 618; Parikh *et al.* 2002, 1058.

¹⁴ Lungu 2011, 25; Meyers 2008, 618.

¹⁵ Atanassova-Timeva, Galabova 2015, 63; Aufderheide *et al.* 1998, 27; Bultheel *et al.* 2016, 33; Mann 1993, 224; Ortner 2003, 128.

¹⁶ Samuelson, Coleman 1976, 1132.

¹⁷ Aufderheide *et al.* 1998, 26; Ortner 2003, 133–134.

¹⁸ Carmichael 1981, 184; Howard *et al.* 1998, 80; Meyers 2008, 618; Mogere *et al.* 2014, 61; Nishio *et al.* 2010, 270; Resnick, Niwayama 1995, 4577.

¹⁹ Rodríguez-Martín 2006, 211; Schwarz 2015.

²⁰ Meyers 2008, 618.

²¹ Meyers 2008, 618; Mogere *et al.* 2014, 61; Parikh *et al.* 2002, 1058; Schwarz 2015.

²² Mogere *et al.* 2014, 61.

²³ Aufderheide *et al.* 1998, 26; Carmichael 1981, 184; Meyers 2008, 618.

²⁴ Rodríguez-Martín 2006, 211; Carmichael 1981, 185.

²⁵ Meyers 2008, 618; Ortner 2003, 450; Uehlinger 1936.

²⁶ Aufderheide *et al.* 1998, 27.

²⁷ Ortner 2003, 158.

²⁸ Aufderheide *et al.* 1998, 27.

²⁹ Miladinović-Radmilović 2011, 178, 179.

mass in the muscle tissue develops within 2–6 weeks after trauma (according to some authors, this period is 3–4 weeks), but needs at least 3–6 months to develop to mature bone.¹⁹ Lesions located within muscle are often well-defined, ovoid or spheroid, and sometimes lacy, ranging in size from 2 to 12 cm.²⁰

Any part of the body may be affected, but it tends to develop over the shaft of long bones, areas where muscles are prone to direct trauma. Some 60% to 75% of reported cases of *myositis ossificans* occur as a result of trauma, the rest are due to total hip arthroplasties, paraplegia, chronic inflammation, immobility, polio, coma, tetanus or burns, etc.²¹

The two most commonly affected anatomical areas are the anterior thigh (quadriceps femoris muscle) and the arm (brachialis muscle), with an incidence of 51.9–56% at the femur, and 12–25% at the humerus, but the temporalis and masseter muscles of the jaw can also be affected.²² Therefore, lesions occur mostly in the upper legs, then in the trunk, proximal limbs, upper extremities, hips/buttocks, hands or wrists and temporalis or pterygoid muscles.²³

DIFFERENTIAL DIAGNOSIS

It is necessary to differentiate between this condition and paleopathological cases such as *myositis ossificans progressiva*, osteochondroma, osteosarcoma or other malignant primary or secondary bone tumours.²⁴ The important factor to evaluate in differential diagnosis is the anatomical location of the lesion. *Myositis ossificans progressiva* is a rare hereditary disease which causes symptoms from early infancy and involves several muscles (heterotopic ossification occurs simultaneously at multiple sites and morbidity and early mortality in children is due to respiratory difficulties and improper treatment).²⁵ *Myositis ossificans traumatica* is rarely encountered in children and does not imply genetic mutations. When attached to bone, lesions of myositis ossificans traumatica usually occur at the origin or insertion of tendons or ligaments. Tumours may arise at these sites as well but they are often irregular

and commonly demonstrate an obvious relationship to their origin in the bone.²⁶ Enthesopathies also occur at sites of tendon and ligament insertion, but the pathogenesis of enthesopathy differs from *myositis ossificans traumatica* in that the bony projections are probably the result of repeated hard use of the muscle over a relatively long duration of time rather than a single traumatic event, as is the case in *myositis ossificans traumatica*.²⁷ Exostosis in this case are smaller and often related to the epiphyseal line.²⁸ Enthesopathies tend to be a much less severe manifestation of abnormal mineralising connective tissue than is the case in *myositis ossificans traumatica*.

CONCLUSION

The overall paleopathological findings of this young male comprehend a healed bone fracture of the right femur followed by severe *myositis ossificans traumatica*. The bone fracture caused unevenness in bone length of the femurs, that is to say, difficulties in walking, which also had effects on other bones of the postcranial skeleton, namely, osteoarthritis, deformations of several bones, dislocations of certain joints, etc.

Unfortunately, from the preserved old medical records, we could not see how doctors treated these bony lesions in the Late Roman period. However, what can be seen from these skeletal remains is that, on the basis of very pronounced muscular, ligamentous and tendinous entheses recorded on the right and left clavicles, on the right and left bladder, on the ribs and bones of the upper extremities, as well as on the dislocation of the shoulders joints and curvature of both ulnae, this person probably relied on medical aid for a long time, that is, on crutches.

In the anthropological literature there are very few published cases of *myositis ossificans traumatica* from the archaeological context. In our country, it was found only in one case in Sirmium (juvenile female (?) individual, 18 years old).²⁹

Translated by the authors

BIBLIOGRAPHY:

- Atanassova-Timeva, Galabova 2015** – N. Atanassova-Timeva, B. Galabova, Paleopathological Changes in the Human Postcranial Skeletal Remains from the Necropolis in the Locality of Saint Spas, in the Varosh Quarter, Town of Pernik, Western Bulgaria (15th–19th Centuries), *Acta morphologica et anthropologica* 22, 2015, 57–65.
- Aufderheide et al. 1998** – A. C. Aufderheide, C. Rodríguez-Martin, O. Langsjoen, *The Cambridge Encyclopaedia of Human Paleopathology*. Cambridge: University Press 1998.
- Bass 1995** – W. M. Bass, *Human Osteology, A Laboratory and Field Manual*. Columbia: Missouri Archaeological Society 1995.
- Buikstra, Ubelaker 1994** – J. E., Buikstra, D. H., Ubelaker, *Standards for data collection from human skeletal remains*, Arkansas Archeological Survey Research Series, No. 44. Fayetteville, Arkansas: Arkansas Archeological Survey 1994.
- Bultheel et al. 2016** – M. Bultheel, J. H. Kirby, J. T. Viljoen, P. L. Viviers, An atypical presentation of myositis ossificans, *South African Journal of Sports Medicine* 28 (1), 2016, 33–34.
- Carmichael et al. 1981** – S. W. Carmichael, S. L. Burkart, R. D. Johnson, Myositis Ossificans: Report of an Unusual Case, *The Journal of Orthopaedic and Sports Physical Therapy* 2, (4), 1981, 184–186.
- Ђурић-Срејић 1995** – М. Ђурић-Срејић, *Увод у физичку антропологију древних популација*, Београд 1995 (М. Ђурић-Срејић, *Увод у физичку антропологију древних популација*, Београд 1995).
- Ferembach et al. 1980** – D. Ferembach, I. Schwidetzky, M. Stloukal, Recommendations for age and sex diagnosis of skeletons, *Journal of Human Evolution* 7, 1980, 517–549.
- Howard et al. 1998** – C. B. Howard, S. Porat, E. Bar-On, M. Nyska, D. Segal, Traumatic Myositis Ossificans of the Quadriceps in Infants, *Journal of Pediatric Orthopaedics B*, 7(1), 1998, 80–82.
- Işcan et al. 1984a** – M. Y. Işcan, S. R. Loth, R. K. Wright, Metamorphosis at the sternal rib end: A new method to estimate age at death in males, *American Journal of Physical Anthropology* 65, 1984, 147–156.
- Işcan et al. 1984b** – M. Y. Işcan, S. R. Loth, R. K. Wright, Age estimation from the rib by phase analysis: White males, *Journal of Forensic Sciences* 29, 1984, 1094–1104.
- Işcan et al. 1985** – M. Y. Işcan, S. R. Loth, R. K. Wright, Age estimation from the rib by phase analysis: White females, *Journal of Forensic Sciences* 30, 1985, 853–863.
- Lovejoy et al. 1985** – C. O. Lovejoy et al., Chronological metamorphosis of the auricular surface of the ilium: A new method for the determination of skeletal age at death, *American Journal of Physical Anthropology* 68, 1985, 15–28.
- Lungu 2011** – S. G. Lungu, Myositis Ossificans – Two Case Presentations, *Medical Journal of Zambia* 38 (2), 2011, 25–31.
- Mann 1993** – G. E. Mann, Myositis Ossificans in Medieval London, *International Journal of Osteoarchaeology* 3, 1993, 223–226.
- Meyers 2008** – S. P. Meyers, *MRI of Bone and Soft Tissue Tumors and Tumor like Lesions. Differential Diagnosis and Atlas*, Thieme, Stuttgart-New York 2008.
- Mikić 1978** – Ž. Mikić, O antropološkoj metodologiji terenske obrade skeletnih nalaza. *Godišnjak Centra za balkanološka ispitivanja ANUBiH* 16/14, 1978, 3–44; 201–242.
- Miladinović-Radmilović 2011** – N. Miladinović-Radmilović, *Sirmium – Necropolis*. Beograd: Arheološki institut, Sremska Mitrovica: Blago Sirmijuma 2011.
- Mogere et al. 2014** – V. Mogere, D. S. Thyagarajan, K. J. Fairbairn, A. Wallace, Myositis ossificans of the humeral insertion of pectoralis major, *International Journal of Shoulder Surgery* 8, 2014, 61–64.
- Nishio et al. 2010** – J. Nishio, K. Nabeshima, H. Iwasaki, M. Naito, Non-traumatic myositis ossificans mimicking a malignant neoplasm in an 83-year-old woman: a case report, *Journal of Medical Case Reports* 4, 2010, 270.
- Ortner 2003** – D. J. Ortner, *Identification of Pathological Conditions in Human Skeletal Remains* (second edition), Amsterdam, Boston, London, New York, Oxford, Pariz, San Diego, San Francisco, Singapore, Sydney, Tokyo: Academic Press 2003.
- Parikh et al. 2002** – J. Parikh, H. Hyare, A. Saifuddin, The imaging features of post-traumatic myositis ossificans, with emphasis on MRI, *Clinical Radiology* 57 (12), 2002, 1058–1066.
- Resnick, Niwayama 1995** – D. Resnick, G. Niwayama, Soft tissues, in: *Diagnosis of Bone and Joint Disorders*, 3rd, D. Resnick (ed.), Philadelphia: Saunders, 1995, 4491–4622.
- Rodríguez-Martín 2006** – C. Rodríguez-Martín, Identification and Differential Diagnosis of Traumatic Lesions of the Skeleton, in: *Forensic anthropology and medicine*, A. Schmitt, E. Cunca, J. Pinheiro (eds), Humana Press 2006, 197–221.
- Samuelson, Coleman 1976** – K. M. Samuelson, S. S. Coleman, Nontraumatic Myositis Ossificans in Healthy Individuals, *JAMA* 235 (11), 1976, 1132–1133.
- Schwarz 2015** – L. S. Schwarz, Myositis ossificans and related ailments, Paleopathology Association Scientific Program 42 and Annual North American Meeting St. Louis, Missouri March, 2015, poster presentation (https://www.researchgate.net/publication/290315618_Myositis_ossificans_and_related_ailments).
- Trotter, Gleser 1952** – M. Trotter, G. C. Gleser, Estimation of stature from long bones of American whites and Negroes, *American Journal of Physical Anthropology* 10, 1952, 463–514.
- Uehlinger 1936** – E. Uehlinger, Myositis ossificans progressive, *Ergebnisse der Strahlenforschung* 7, 1936, 175–220.

Резиме: ДРАГАНА ВУЛОВИЋ, Археолошки институт, Београд
НАТАША МИЛАДИНОВИЋ РАДМИЛОВИЋ, Археолошки институт, Београд
ИЛИЈА МИКИЋ, Археолошки институт, Београд

СЛУЧАЈ *MYOSITIS OSSIFICANS TRAUMATICA* НА СКЕЛЕТУ ИЗ ВИМИНАЦИЈУМА

Кључне речи – *Viminacium*, касна антика, локалитет Пећине, *myositis ossificans traumatica*, прелом кости

Римски град и војни логор Виминацијум налази се између села Стари Костолац и Дрмно, на 12 km североисточно од Пожаревца, у близини ушћа Млаве у Дунав (карта 1). Током своје историје постао је највеће урбано насеље и главни град провинције Горње Мезије (*Moesia Superior*), касније Прве Мезије (*Moesia Prima*). На некрополи Пећине у гробу G-5785, из касноантичког периода, откривени су скелетни остаци јувенилне особе мушког пола, старе 20–25 година (сл. 1; табеле 1–3).

Палеопатолошка анализа је показала присуство сраслог, највероватније спиралног, прелома са антеверзијом (?) у горњој половини тела десног фемура, праћеног *myositis ossificans traumatica*-ом на постериорној страни тела. На *linea aspera*-и егзостоза је извучена ка медијалној страни (табла I/1–4). Осим прелома, константован је и благи остеоартритис на тарзалним костима и *osteochondritis dissecans*, односно посттрауматична субартуларна некроза (пречника 1,7 cm) на медијалном кондилу левог фемура (табла I/5). На десној скапули видљива је дислокација гленоидалног удубљења, и то испод самог удубљења, изнад *m. triceps brachii – Caput longum* (табла II/4, 5). Постериорно је на сакруму уочена дислокација једног сегмента (табла I/6). На обе илијачне кости, изнад аурикуларне површине, приметни су сулкуси (табла II/6, 7).

Изражене ентезе мишића, лигамената и тетива видљиве су на: оба хумеруса (табла II/3), на обе улне, на оба радијуса, на обе клавикуле, на обе скапуле, на два ребра, на обе карличне кости, на оба фемура (на десном фемуру су припоји израженији). Такође, на улнама су приметна, поготово са постериорне стране у горњој половини тела, и латерална закривнућа тела (табла II/1, 2).

Myositis ossificans (traumatic myositis ossificans, heterotopic ossification, ectopic ossification, neurogenic ossifying fibromyopathy, reactive Mesenchymal proliferation, ossifying hematoma, pseudomalignant osseous tumour of soft tissues) представља локализоване не-неопластичне, репаративне коштане лезије, које се састоје од реактивног хиперцелуларног фиброзног ткива, хрскавице и/или кости у мишићу или меком ткиву. Може настати као последица прелома, као што је овде случај, или услед трауме (активне или хроничне) или тупе повреде која доводи до дубоког крварења у ткиву. Понављајуће мање трауме, које се понекад виде на унутрашњој страни бутине код коњаника, такође могу довести до *myositis ossificans*-а. Код савремене популације, *myositis ossificans* се може развити код особа које су имале операције (посебно

замену кука), спортске повреде или несреће, као и код особа које имају параплегију.

Myositis ossificans се према Самјуелсону и Колману може класификовати у четири подтипа: 1) *myositis ossificans progressiva*, 2) *myositis ossificans traumatica*, 3) *myositis ossificans* који је у вези с неуромишићним и хроничним обољењима и 4) не-трауматични *myositis ossificans*. *Myositis ossificans traumatica* настаје авулзијом тетива или мишићних припоја, при чему се ствара хематом, који с временом може нестати, али мишићно ткиво повређено, као одговор на трауму, ствара кост директно у мишићном ткиву, често и у вези с хематомом. Новонастала калцификована и, често, осификована коштана фиброзна маса представља лезију познату као *myositis ossificans traumatica (post-traumatic myositis ossificans, myositis ossificans circumscripta)*. Ова маса може бити у потпуности одвојена од кости или може постати њен део. Најчешће се појављује код физички активних адолесцената (ретко се јавља код деце млађе од 10 година) и одраслих особа млађих од 30 година, код особа које су физички активне, и са већом учесталашћу код мушкараца (однос међу половима: М/Ф је 1,2/1–2,2/1). На скелетима древних популација често је видљив у виду неправилно обликованих коштанних израсталина које су срасле са дугим костима (дужине 2–12 cm). Било који део тела може бити погођен *myositis ossificans traumatica*-ом, али најчешће се јавља на телу дугих костију, деловима где су мишићи склони директној трауми. Око 60–75% забележених случајева *myositis ossificans*-а јесу последица трауме, док су остали случајеви последица операције замене кука, параплегије, хроничних упала, непокретљивости, полиа, коме, тетануса, опекотина итд. Најчешће се појављује на фемуру (*m. quadriceps femoris*), са учесталашћу од 51,9–56%, и на хумерусу (*m. brachialis*), са учесталашћу 12–25%, док је најмања учесталост појављивања на вилици, на *m. temporalis* и *m. masseter*. Приликом дијагностиковања *myositis ossificans traumatica* важно је направити диференцијалне дијагнозе и разликовати то стање од других палеопатолошких промена као што су *myositis ossificans progressiva*, остеохондрома, остеосаркома, или други малигни примарни или секундарни тумори костију, егзостозе, ентезопатије итд.

Палеопатолошки налаз овог младог мушкараца, као што смо већ истакли, показује залечен прелом десног фемура, праћен озбиљним *myositis ossificans traumatica*. Прелом је проузроковао скраћење дужине десног фемура, што је касније изазвало читав низ других проблема: потешкоће у ходању,

појаву остеоартритиса, деформације неколико костију, дислокације одређених зглобова итд. Нажалост, из сачуваних античких медицинских извора нисмо могли да видимо како су лекари у касноримском периоду лечили такве лезије на костима, али оно што се види из остеолошког материјала – засновано на веома израженим ентезама мишића, лигаментата и тетива видљивим на обе клавикуле, на обе скапуле,

на ребрима и костима горњег екстремитета, као и на дислокацији раменских зглобова и закривљености обе улне – јесте то да се ова особа вероватно дуго ослањала на штаке.

У антрополошкој литератури постоји веома мало публикованих случајева *myositis ossificans traumatica*. Код нас је пронађен још само у Сирмијуму, код јуvenilне индивидуе женског (?) пола, старе 18 година.

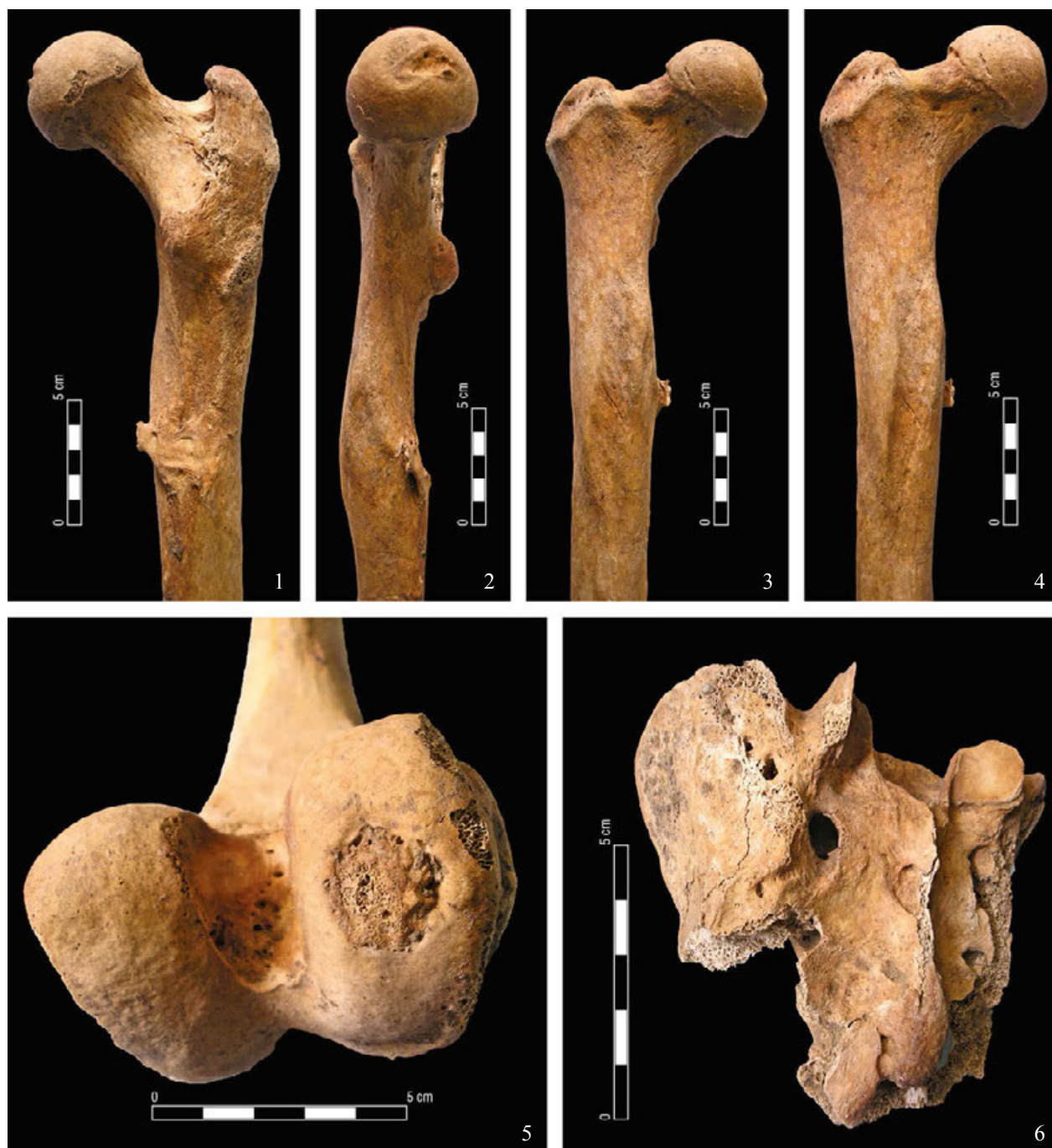

Plate I – 1–4) healed fracture of the right femur and myositis ossificans traumatica on the posterior side of the body; 5) osteochondritis dissecans on the medial condyle of the left femur; 6) dislocation of one of the segments on the posterior part of the sacrum (photo by N. Miladinović-Radmilović)

Табла I – 1–4) срасиџао њрелом на десном фемуру и myositis ossificans traumatica на њосџериорној сџрани њела фемура; 5) osteochondritis dissecans на медијалном кондилу левој фемура; 6) дислокација једној сејмениџа на њосџериорној сџрани сакрума (фотоџографисала Н. Миладиновић-Рагмилиовић)

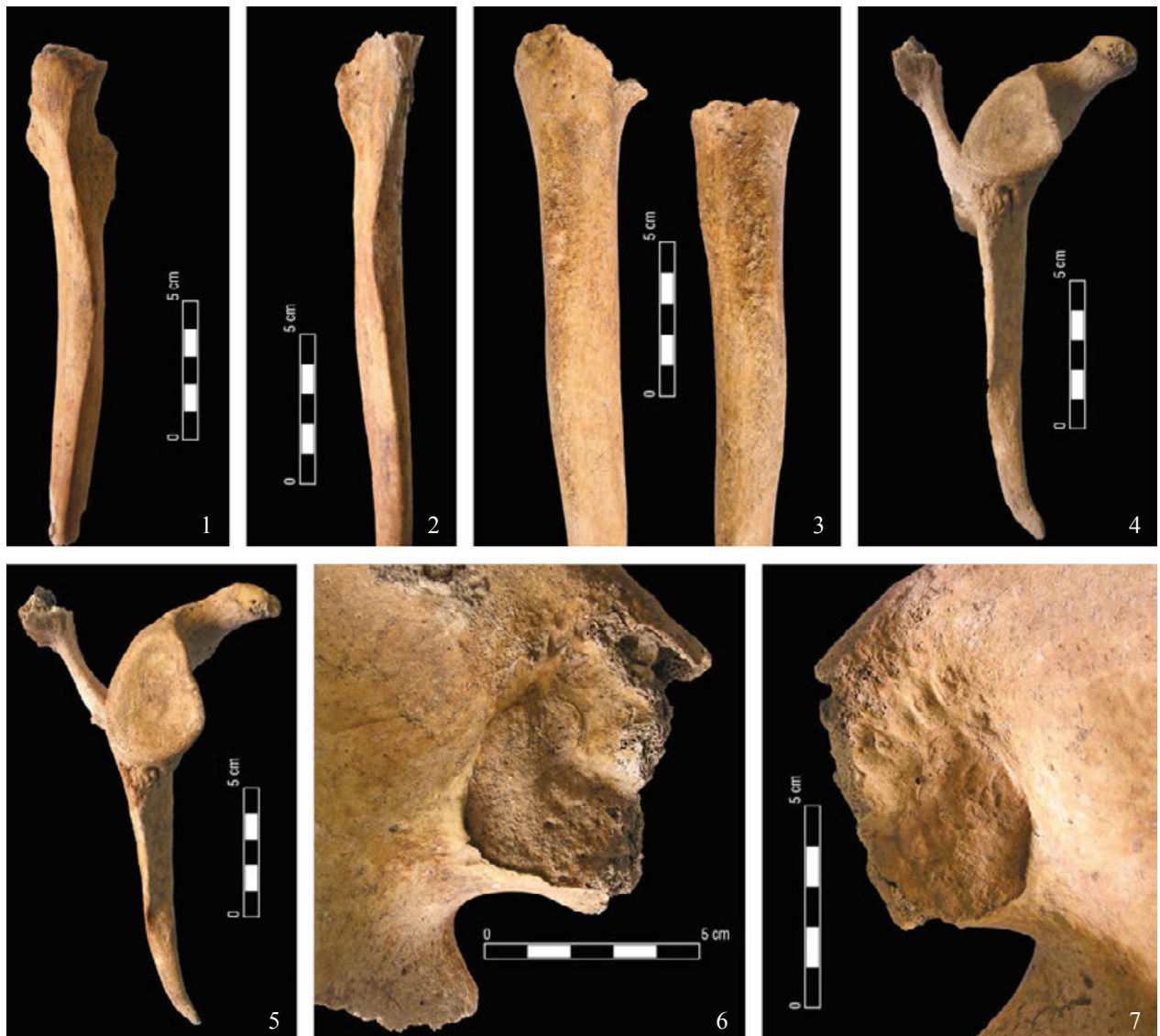


Plate II – 1–2) lateral curvatures of the body on both ulnae; 3) prominent muscular entheses on both humeri; 4–5) dislocation of the glenoid cavity on the right scapula; 6–7) prominent sulci above both the auricular surfaces, on both iliac bones (photo by N. Miladinović-Radmilović)

Табла II – 1–2) латерална закривнућа тела обе улне; 3) изражене мишићне енџезе на оба хумеруса; 4–5) дислокација гленоидалној удубљења на десној скапули; 6–7) изражени сулкуси изнад обе аурикуларне површине, на обе илијачне кости (фотографисала Н. Миладиновић-Радомиловић)