

MILITARY GRAVES FROM THE LATE ROMAN NECROPOLIS AT SLOG IN RAVNA (*TIMACUM MINUS*)

UDK: 904:726.8"652"(497.11)

DOI: 10.2298/STA1464087P

Original research article

e-mail: spetkovi@ai.ac.rs

Received: February 24, 2014

Accepted: July 23, 2014

Abstract. – The necropolises of the Roman fortification and settlement *Timacum Minus*, in the village of Ravna, near Knjaževac, were partially explored by systematic and rescue archaeological excavations. The most extensively explored was the part of the Late Roman necropolis on the eastern slope of the Slog hill, about 400m west of the fortification, where 80 graves from this period have been investigated. The analysis of the human osteological material, and the archaeological finds from the aforementioned necropolis, confirmed 17 military graves, containing adult male individuals with traces of injuries, stress markers and pathological changes, characteristic of a military population, as well as military equipment and weapons. At the time of the formation of the Late Roman necropolis at the site of Slog, during the second half of the 4th and the first half of the 5th century, the garrison of the *Timacum Minus* fortification consisted of an equestrian unit of *pseudocomitatenses Timacenses*, a part of the auxiliary formation that secured the forts and roads in the Timok region. Among the graves from the three phases of the Late Roman necropolis, similarities as well as certain differences are apparent, indicating changes in the structure of the civilian and military population of *Timacum Minus*.

Key words. – Late Roman period, necropolis, *Timacum Minus*, Roman army, Chernyakhov culture, sharp force traumas, blunt force injuries, injuries inflicted by an arrow.

The Roman fortification and settlement on the left bank of the Beli Timok, in the vicinity of the village of Ravna, 10 km north of Knjaževac, was, using systematic archaeological explorations, identified as *Timacum Minus* (Map 1).¹ There are several hypotheses regarding the nature of this Roman site, however, the most credible assumption is that it was a fortified administrative centre of the Upper Moesia mining region *Territoria metallorum*, which comprised the north-eastern part of the Upper Moesia province, later the provinces of *Dacia Ripensis* and *Dacia Mediterranea*.² The fortification was first established

as far back as the end of the 1st century AD, but it was abandoned after the Hun invasion of the Danube Basin in the middle of the 5th century (Fig. 1).³

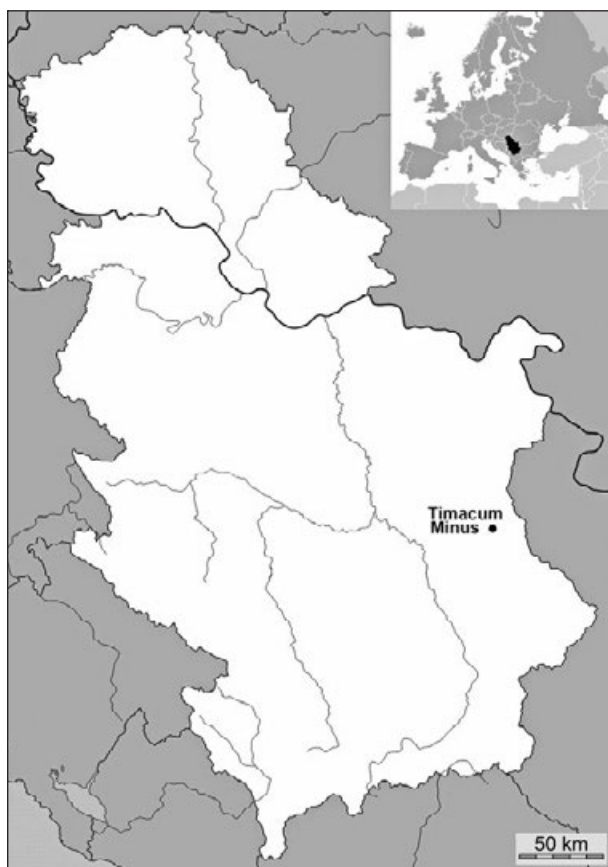
Around the fortified administrative, mining-metal-lurgical and craft centre, an urban settlement with public

¹ Petrović 1995, 21–37; Петровић, Јовановић 1997, 18–19.

² Душанић 1980, 32–34; Petrović 1996, 195 *et sequ*; Dušanić 1996, 224, Note 39.

³ Петковић, Јовановић 2000, 277–280; Petković *et al.* 2005, 13–17; Илијić 2009, 11–13.

* This article is the result of the project: *Romanisation, urbanisation and transformation of urban centres of civil, military and residential character in Roman provinces in the territory of Serbia* (no. 177007), funded by the Ministry of Education, Science and Technological Development of the Republic of Serbia.



Map 1. Position of the archaeological site Timacum Minus on the map of the Republic of Serbia

Карта 1. Положај археолошкој налазиштва Timacum Minus на карти Републике Србије

baths, villas, workshops and temples was formed over time. Some of these structures were confirmed by archaeological excavations, whilst the others were acknowledged indirectly, through the discovered sculptures and epigraphic monuments. Based on the latter, which were built into the walls and buildings during reconstruction in the Late Roman period, from the middle of the 3rd to the first half of the 5th century, the existence of a large necropolis in the 2nd and 3rd centuries was ascertained.⁴ Unfortunately, for the mentioned reason, most of the gravestones had been dislocated, thus, very little is known about this necropolis. More recent non-destructive archaeological exploration, which used geophysical methods of measuring,⁵ along with the data gathered from locals, who work the fields and gardens west of the Roman fortification, locate the necropolis of the cremated deceased from the 2nd–3rd century to the stretch of Širina situated

between the fortification in the east, the Ropinski brook in the north, the Slog hill in the west and the Seliški (Zubanov) brook in the south (Plan 1). On the other hand, parts of the Late Roman necropolis were explored on the right bank of the Ropinski brook, to the north-west of the fortification and on the eastern slope of the Slog hill.

In the course of the three campaigns of rescue archaeological excavations, prompted by the reconstruction of the local Ravna – Debelica road in 1994–1996, on the left side of the road, on the eastern slope of the Slog hill, a section of the multilayered Late Roman and Early Medieval necropolis was explored. 140 graves were discovered, out of which 72 with 75 buried individuals are from the Late Roman period (Plan 2). It was concluded that it was a necropolis formed in three successive phases in the period from the middle of the 4th to the middle of the 5th century: phase I – from 350 to 380, phase II – from 380 to 410 and phase III – from 410 to 450.⁶ The results of the rescue archaeological excavations of the Slog necropolis were published in 2005 in a separate monograph.⁷ On that occasion, the results of the anthropological analysis, carried out by Dr Zsuzsana Zoffmann, the anthropologist of the National Museum in Budapest,⁸ were also published. However, since 2011 a project of processing, analysing and publishing all archaeological data and finds gathered during the systematical and rescue archaeological excavations at the site of Ravna – Timacum Minus⁹ has been in progress. New data,

⁴ Petrović 1995, 13–16, 40; Petković, Ilijić 2013, 64–65, Table 1.

⁵ Илијић 2011.

⁶ Petković *et al.* 2005, 145.

⁷ Petković *et al.* 2005.

⁸ Petković *et al.* 2005, 279–323.

⁹ The Project *Preparation of the monograph of the Roman fortification and the town of Timacum Minus in Ravna near Knjaževac*, co-funded by the Ministry of Culture and Information of the Republic of Serbia and the Municipality of Knjaževac, was carried out in 2010–2012 by the Institute of Archaeology in Belgrade and the Homeland Museum of Knjaževac, with an expert team consisting of: Dr Sofija Petković, senior research associate of the Institute of Archaeology – the head of the project, Dr Nataša Miladinović-Radmić, research associate of the Institute of Archaeology – anthropologist, Bojana Ilijić MA, senior curator of the Homeland Museum of Knjaževac – archaeologist, Nikola Radinović MA, Marija Jović MA and Milica Mitić – archaeologists, Saša Milutinović-Leteći, photographer and Tomislav Živković, conservator of the Homeland Museum of Knjaževac, Dragica Bizjak – senior undergraduate of Archaeology and Nikola Ivanković – senior undergraduate of Architecture.



Fig. 1. Aerial photography of the archaeological site Timacum Minus, taken from the south-east

Сл. 1. Аеро-снимак археолошкој налазиштуа Timacum Minus, са југоисттока

acquired from the revision of the human osteological material and by analyses carried out using modern methodological procedures, led us to reconsider the premises and conclusions that relate to the population of the Late Roman Ravna.¹⁰ This paper will try to supplement the data about the military component of the *Timacum Minus* population, which undoubtedly played a significant role in the socio-economic picture of this settlement.

Within the explored Late Roman graves from the Slog necropolis in Ravna, the burials that contained archaeological finds of military equipment and weapons were singled out (Plan 2). By a detailed anthropological analysis of the osteological finds from these graves, we primarily attempted to determine, as much as was possible given the degree of bone preservation, the presence of ante-mortem and perimortem traumas which occurred, not as a consequence of accidents, but as a result of intentional violence,¹¹ as well as the presence of characteristic markers of occupational stress¹² and pathological changes,¹³ which would indicate that the deceased were in active military service. The graves

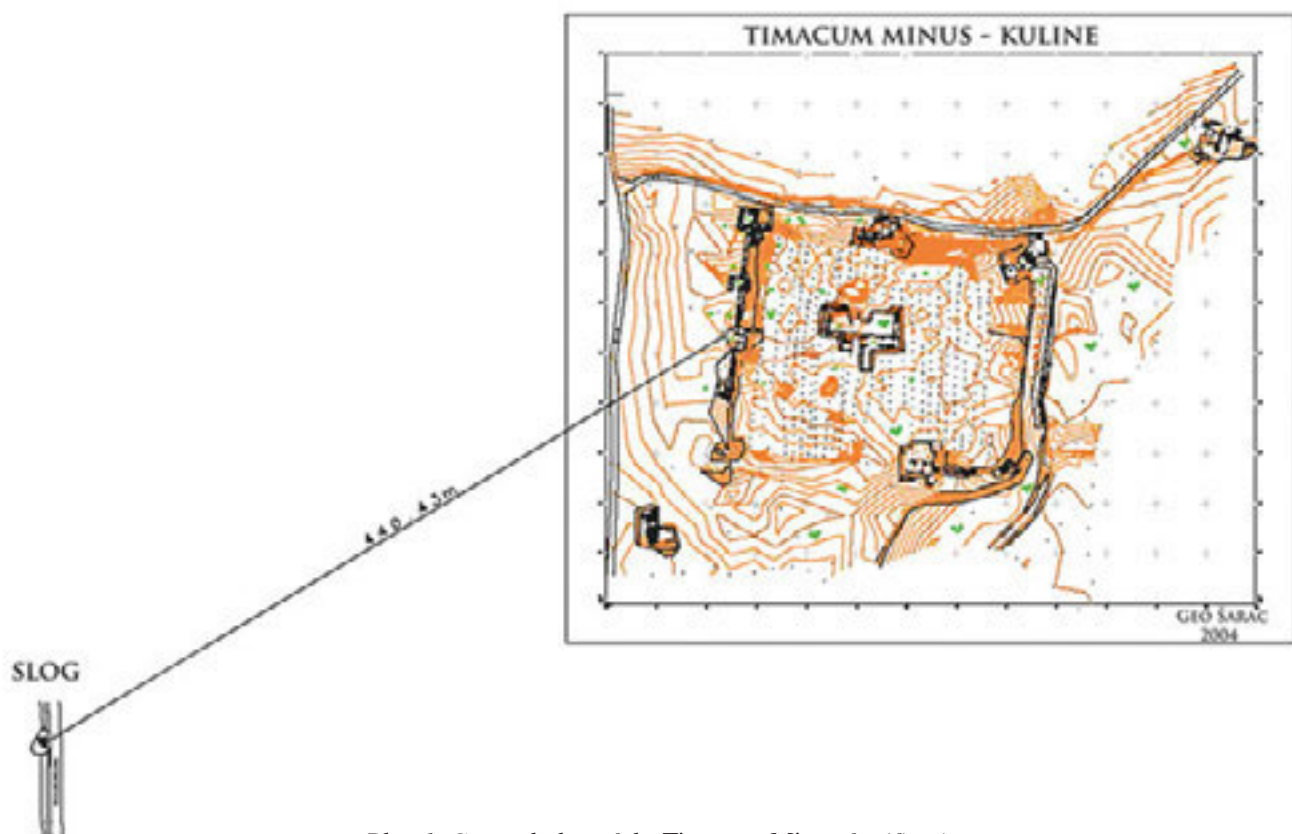
with the aforementioned characteristics were analysed according to the phases of burials at the Late Roman necropolis of Slog in order to acquire, by means of

¹⁰ Petković *et al.* 2005, 143–144.

¹¹ The injuries caused by intentional violence include fractures of the upper and lower jaw, tooth fractures, and fractures of the nose and cheekbones, blows inflicted by hard and sharp objects (stone or hilt of a sword or knife), blows inflicted by hard and blunt objects, injuries caused by sharp or blunt blade, injuries inflicted by projectiles (arrows, stones from a slingshot), etc.

¹² The examination of markers of occupational stress, typical for cavalry and infantry, is very intricate work. In horsemen, for example, there is a whole series of muscle and ligament attachment points in the region of the shoulder and elbow joints, the lower back, the sacroiliac region and in the region of the legs (most frequently the femur). In addition, what should be taken into consideration are the deformities caused by using certain types of weapons (swords, bows, spears and shields), as well as from wearing military equipment (helmets, armour, vests etc.).

¹³ Pathological changes caused by frequently poor living conditions (unvaried diet, poor hygiene conditions, exposure to cold and damp, long gruelling marches, often in full battle dress and general exhaustion due to irregular sleep, stress, infectious diseases, etc.).



Plan 1. General plan of the Timacum Minus fortification, civil settlement and the Late Roman Slog necropolis

План 1. Генерални план утврђења Timacum Minus, цивилној насеља и касноантичке некрополе Слог

comparing data, chronologically relevant results which inform on the development of the military garrison of the *Timacum Minus* fortification, as well as similarities and differences within its function throughout the second half of the 4th and the first half of the 5th century. Subsequently, the correlation between these results and the data acquired by the analysis of the stratigraphy of the cultural layers and the construction phases of the fortification was formulated.

HUMAN OSTEOLOGICAL MATERIAL

The anthropological analysis included 17 individuals (Tables 1, 5 and 10). Based on the archaeological research, the graves were divided into three phases. Phase I (350–380) includes the following graves: 44, 69A, 79, 91, 99 and 141; phase II (380–410) includes graves 15, 25, 26, 27A, 28, 76, 97 and 123; phase III (410–450) includes graves 100, 102 and 108.

METHODOLOGICAL FRAMEWORK

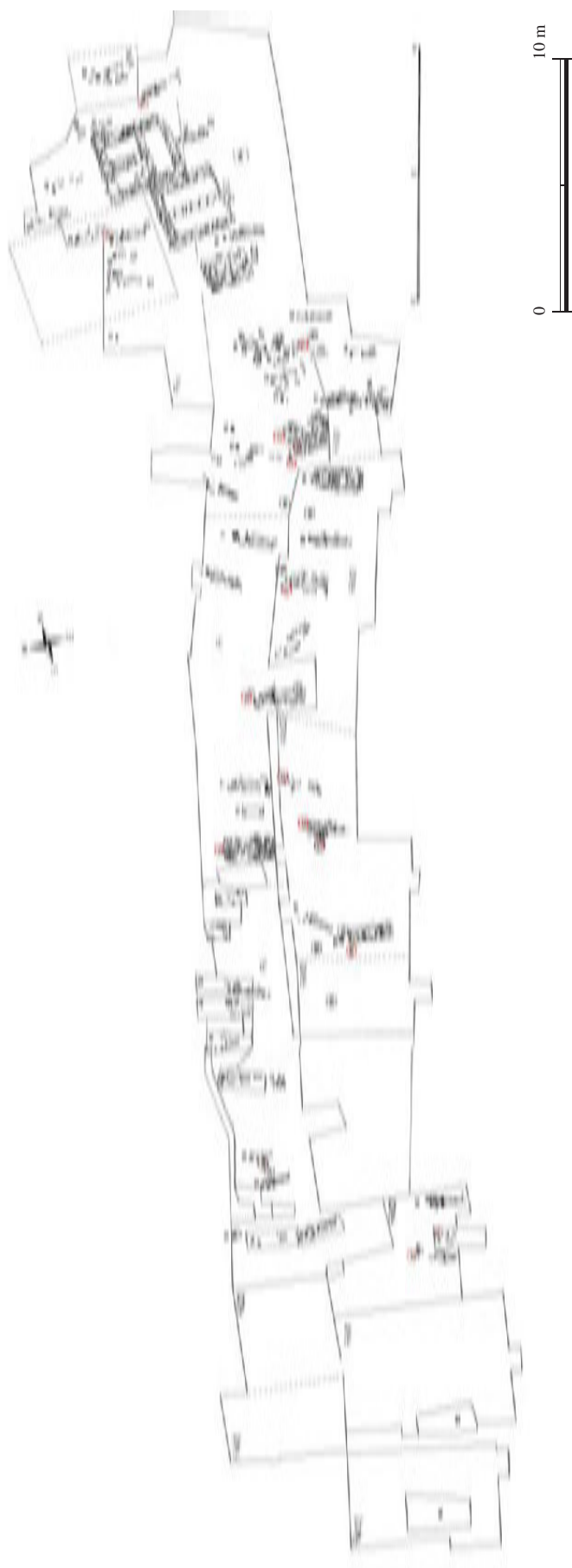
The preservation degree of the examined skeletons is given in the form of a descriptive scheme comprising five categories, as proposed by Mikić:¹⁴ I – complete, well preserved skeleton; II – incomplete, well preserved skeleton; III – moderately preserved skeleton;¹⁵ IV – partially preserved skeletal remains¹⁶ and V – poorly preserved skeletal remains.¹⁷

¹⁴ Mikić 1978, 9.

¹⁵ Moderate preservation refers to the situation when a complete skeleton is present in the grave, but the bones are quite brittle and break in the course of excavation.

¹⁶ Partial preservation refers to the situation when only parts of a skeleton are present in the grave, which are very brittle and cannot be easily lifted, packed and transported.

¹⁷ Poor preservation refers to the situation when skeletal remains can only be registered in traces and are practically impossible to lift completely.



Plan 2. Late Roman phase of the Slog necropolis in Ravna

План 2. Касноантичка фаза некрополе Слої у Равни

For determining sex on skeletal material of juvenile and adult individuals, the combination of morphological and metrical methods was opted for. Special attention was given to the morphological elements of the skull (*glabella*, *planum nuchale*, *processus mastoideus*, *processus zygomaticus*, *arcus superciliaris*, *protuberantia occipitalis externa*, *os zygomaticum*, *tubera frontale et parietale*, the inclination of the *os frontale*, *margo supra-orbitalis* and the shape of the *orbitae*) and the pelvis (*sulcus praeauricularis*, *incisura ischiadica s. ischialis major*, *arcus pubis s. pubicus et angulus subpubicus*, *arc compose*, the appearance of the *os coxae*, *corpus ossis ischii*, *foramen obturatum*, *crista iliaca*, *fossa iliaca*, *pelvis major*, *pelvis minor*; subpubic region: ventral arc, subpubic concavity and the medial appearance of the ischio-pubic branch). The methodology was adopted from a group of European anthropologists¹⁸ and Buikstra and Ubelaker.¹⁹ The morphological elements of the mandible were also analysed (the general appearance of the mandible (*corpus mandibulae*, *ramus mandibulae* and *angulus mandibulae*), *mentum*, *angulus mandibule* and *margo inferior*), according to the criteria established by Ferembach and his associates,²⁰ and metrical elements relevant for sex determination on the skeletons.²¹ Based on the obtained metrical elements, calculated indices were presented in tables separately for each grave (Tables 3, 7 and 12). The mesiodistal and vestibulolingual diameters were measured on the teeth, in the manner recommended by Hillson.²² The differences in tooth size, obtained via these measurements, were monitored mainly on the canines, and when they were missing in the osteological material, other teeth such as molars, premolars and incisors were used.²³ Whilst analysing other bones of the postcranial skeleton, both morphological and metrical elements were also examined. The morphological elements that drew our attention were the degrees of development: *tuberositas deltoideae*, *tuberositas radii* and *margo interosseus* (of radius), *tuberositas ulnae* and *margo interosseus* (of ulna), *linea aspera* and *tuberositas tibiae*. Bone appearance, body curvature and *facies auricularis* were morphological elements observed in the sacrum.²⁴ Metrical elements have a decisive role in sex determination on the skeletal remains of the postcranial skeleton, hence, special attention was paid to them. Based on the acquired metrical elements, the separately calculated indices for the left and the right side of the body were presented in tables for each separate grave (Tables 4, 8, 9 and 13).

The individual ages of the deceased were determined based on: the degree of obliteration of the cranial

sutures (Vallois' scheme);²⁵ changes on maxillary and mandibular teeth (changes were compared on the occlusal surface of the dental material with the numerical classification of the attrition of the upper (occlusal) surface of molars in relation to age, as defined by Brothwell²⁶ and changes on the occlusal surface of the dental material with the numerical classification of the attrition of the upper surface of all teeth in relation to age, as defined by Lovejoy);²⁷ morphological changes in the sternal ends of the ribs (metamorphoses of the depth, joint cavities, shape, edges and ridge configuration were examined, together with the overall state of the bone, based on nine (0–8) phases of progression, covering an age range from 18 to over 70);²⁸ morphological changes on the medial end of the clavicle (morphological changes were observed on the medial end of the clavicle, as documented by Scheuer and Black,²⁹ who established five (1–5) phases of progression, covering an age range from 14 to 29); morphological changes on the joint surface of the pubic symphysis (Todd's method was used here, in which the metamorphosis of the surface of the pubic symphysis is divided into ten chronological phases during ageing, starting with the age of 18, up to 50 and over);³⁰ sacroiliac region (the age of adult individuals was determined based on the model defined by Lovejoy and his associates,³¹ whereby they classified the changes within this region into eight phases, from late adolescence to the phase of old age, devoting most attention to the examination of the position, marginal liping and bone porosity of this region).

26 epigenetic variations on the cranial and 11 on the postcranial part of the skeleton were observed.³²

¹⁸ Ferembach, Schwidetzky and Stloukal 1980, 519–527.

¹⁹ Buikstra and Ubelaker 1994, 15–21.

²⁰ Ferembach, Schwidetzky and Stloukal 1980, 523–525.

²¹ Ferembach, Schwidetzky and Stloukal 1980, 523–525; Bass 1995, 84, 85.

²² Hillson 1990, 240–242; *idem.* 1996, 80–82.

²³ Garn, Lewis and Kerewsky 1965.

²⁴ Mikić 1978, 18, 19; Bass 1995, 114.

²⁵ Vallois 1937.

²⁶ Brothwell 1981, 72.

²⁷ Lovejoy 1985.

²⁸ Işcan, Loth and Wright 1984a; *idem.* 1984b; *idem.* 1985.

²⁹ Scheuer and Black, 2000.

³⁰ Todd 1920, 285–334; *idem.* 1921a; *idem.* 1921b.

³¹ Lovejoy *et al.* 1985.

³² Hauser and De Stefano 1989; Ђурић-Срејић 1995, 238–260.

The stature of juvenile and adult individuals was calculated based on formulae established by Trotter and Gleser (Tables 2, 6 and 11).³³

CATALOGUE OF GRAVES WITH ANTHROPOLOGICAL ANALYSIS³⁴

PHASE I OF THE NECROPOLIS (350–380) (Pl. I)

Grave 44

Sondage F I/1994.

Freely dug burial pit, with bottom at a relative depth of 1.80 m. The find of an iron nail in the vicinity of the left foot indicates the existence of a wooden casket.

Orientation: west-east, with a 10° deviation towards the north.

Skeleton supine with legs extended.

Finds (Pl. III, 1):

1. small beads of glass paste near the left knee,
2. a bronze crossbow fibula near the left lower leg (Pl. II, 1),³⁵
3. a glass bottle near the left lower leg,³⁶
4. a bronze belt buckle with an oval plate and a frame shaped like the Latin letter B, near the left lower leg (Pl. II, 2),³⁷
- 5–6. bronze shoe buckles with rectangular plates and frames shaped like the Latin letter D, near the left and right feet (Pl. II, 3),³⁸
- 7–8. leaf-shaped, bronze, shoe strap-ends near the left and right feet (Pl. II, 4),³⁹
9. two bronze coins of Constantius II, minted in the period 337–348, next to the left foot,⁴⁰
10. an iron nail, below the left foot.

Note: The grave is located below the Late Roman graves 26 and 27, which partially damaged it. The human osteological material and coin finds from grave 26 possibly belong to this grave.

ANTHROPOLOGICAL ANALYSIS:

In the grave, skeletal remains of a male (?) juvenile/adult individual, aged 20–24 (dental age), were discovered.⁴¹

The only paleopathological change detected is the dislocation of the left ankle joint.

Dental analysis of tooth 22 indicated moderately pronounced calculus and abrasion of the 2nd degree (exposed dentin).

Markers of occupational stress in the form of hypertrophy (cortical defect) are visible on the tendon attachment point of the left calcaneus (*tendo calcaneus (Achillis)*).

Grave 69A

Sondage F II/1995.

Rectangular burial pit, dug into the subsoil (green-yellowish marl), dimensions: 2.30 x 0.80 m, with bottom at a relative depth of 1.80 m.

Orientation: west-east.

Skeleton supine with legs extended and hands on pelvis.

Finds:

1. a conical glass goblet near the pelvis (Pl. II, 5),⁴²
2. a bronze crossbow fibula near the right forearm (Pl. II, 6).⁴³

Note: It was damaged by the subsequent digging of the Late Roman graves 53 and 58.

ANTHROPOLOGICAL ANALYSIS.⁴⁴

In the grave, skeletal remains of an adult individual, of unknown sex, aged 30+ were discovered.⁴⁵

³³ Trotter and Gleser 1952.

³⁴ Although the monograph from 2005 (Petković *et al.* 2005, 25–46, 49–126) contains catalogues of all explored graves and finds, a military graves catalogue is presented and considered in the article due to certain additions and corrections which mainly relate to the analysis of anthropological and archaeological material.

³⁵ Petković 2010, 264–266, sl. 93, kat. 1537 – type 34/D 2 is dated to the period of the Valentinian Dynasty and Theodosius I (363–395).

³⁶ The glass bottle had been damaged to such an extent that the reconstruction of its shape was not possible.

³⁷ Petković *et al.* 2005, 91, Cat. 2, Fig. 18b, Pl. 10, 3 – is dated to the second half of the 4th century.

³⁸ Petković *et al.* 2005, 97, Cat. 1, Pl. VI, G. 44, 5–6, Pl. 5, 3 – is dated to the second half of the 3rd and the 4th century.

³⁹ Petković *et al.* 2005, 97, Cat. 2, Pl. VI, G. 44, 7–8, Pl. 5, 3 – is dated to the 4th century.

⁴⁰ Petković *et al.* 2005, 116, Cat. 7, 9, Pl. 5, 3.

⁴¹ Degree of bone preservation: category IV (partially preserved cranial and postcranial skeleton).

⁴² Ružić 1994, 51, tip VII/12b, T. XXXVIII, 6, T. XL, 3 – is dated to the second half of the 4th and the first half of the 5th century.

⁴³ Petković 2010, 266–269, sl. 97, T. LXVIII, 1, kat. 1635 – type 34/E 1 is dated to the period of the reign of Theodosius I and Arcadius (380–408).

⁴⁴ In the same grave, the partially preserved postcranial skeletal remains of an adult female (?) individual, of unknown age (Grave 69) were also discovered.

INDIVIDUAL AGE	MALE		FEMALE		UNDETERMINED SEX		TOTAL	
juvenilis I (15-18 years)	-	-	-	-	-	-	-	-
juvenilis II (19-22 years)	1	-	-	-	-	-	1	-
adultus I (23-30 years)	-	1	-	-	-	-	-	1
adultus II (31-40 years)	-	-	-	-	1	-	1	-
maturus I (41-50 years)	-	-	-	-	-	-	-	-
maturus II (51-60 years)	1	-	-	-	-	-	1	-
senilis I (61-70 years)	-	-	-	-	-	-	-	-
senilis II (71 and more)	-	-	-	-	-	-	-	-
unknown age	2				-		2	
TOTAL NUMBER OF INDIVIDUALS	5		-		1		6	

Table 1. Sex and age structure of individuals

Табела 1. Полна и старосна структура индивида

Paleopathological changes were not noticed.

Markers of occupational stress in the form of hypertrophy (cortical defect) are visible on the ligament attachment point of the left femur (*lig. capitis femoris*).

Grave 79

Sondage F I (V)/1995.

Freely dug burial pit, with bottom at a relative depth of 1.00 m.

Orientation: west-east.

Skeleton supine with legs extended.

Finds:

1–2. a consecration coin of Constantine I from 341–346 and a coin of Constantius II, minted between 341–348, near the right foot,⁴⁶

3. two fragments of bronze plating,

4. an atypical fragment of a glass vessel.

Note: The upper part of the skeleton was destroyed by grave robbers. The grave is situated below the Late Roman graves 38 and 32.

ANTHROPOLOGICAL ANALYSIS:

In the grave, skeletal remains of an adult male individual, of unknown age, were discovered.⁴⁷

The only paleopathological change detected is the dislocation of the right ankle joint.

Markers of occupational stress in the form of hypertrophy (cortical defect) are visible on the muscle attach-

ment points of both femurs (all muscle attachment points are pronounced along the *lineae asperae*). Markers of occupational stress in the form of hypertrophy (cortical defect) are also visible on the ligament attachment points of both femurs (*lig. cruciatum posterius*, *lig. cruciatum anterius*). On the left tibia, two so-called “squatting facets” are noticeable.

Grave 91

Sondage F I (VI)/1995.

A destroyed grave construction of stone and bricks, with the bottom of the burial pit at a relative depth of 1.25 m. 10 iron nails, arranged above the head, near the right upper leg and below the feet, testify to the existence of a wooden casket.

Orientation: west-east, with a 20° deviation towards the north.

Skeleton supine with legs extended and arms straight, placed alongside the body.

No finds.

Note: The grave was damaged by grave robbers.

⁴⁵ Degree of bone preservation: category IV (partially preserved postcranial skeleton).

⁴⁶ Petković *et al.* 2005, 115–116, Cat. 6, 10, Pl. 11, 1, 4.

⁴⁷ Degree of bone preservation: category IV (partially preserved postcranial skeleton).

STATURE (cm)	GRAVE 91	GRAVE 141
humerus	-	168 ± 5
radius	-	165 ± 5
ulna	-	-
femur	176 ± 4	168 ± 4
tibia	-	-
fibula	-	-
medium	176 ± 4	167 ± 5

Table 2. Stature

Табела 2. Телесна висина

ANTHROPOLOGICAL ANALYSIS:

In the grave, skeletal remains of an adult male individual, aged 50+ were discovered.⁴⁸

The perceived paleopathological change is a trace of an injury in the form of a cut on the left side of the mentum (Pl. IV, 1). The cut could have been inflicted by a right-handed person with a short dagger or sword in a close frontal clash. Other noticeable paleopathological changes are a fused fissure in the lower half of the body of the right tibia, on the anterior side, osteoarthritis on the glenoid cavities of both scapulae and mild traces of *cribra orbitalia* on the right orbit roof.

Dental analysis indicated the presence of the following teeth in the jaws: 11, 12, 13, 14, 15, 21, 22, 23, 24, 27, 31, 32, 33, 34, 35, 36 (root), 37, 38, 41, 42, 43, 44, 45 (root) and 46 (root). Teeth 16, 25, 26 (?), 28, 47 (?), 48 (?) were lost ante-mortem, and tooth 28 (?) post-mortem. Abrasion of the 1st degree (in enamel) was noted on tooth 27, of the 2nd degree (exposed dentin) on teeth 22 and 44, of the 3rd degree (to the bottom of the fissure) on teeth 11 (→ 4th), 12 (→ 4th), 15, 21 (→ 4th), 35, 38, 42 (→ 4th) and 43, and of the 4th degree (pulp exposure) on teeth 13, 14, 23, 24, 31, 32, 33, 34, 37 and 41. Parodontopathy is very pronounced on the maxilla, and moderately on the mandible. Hypoplasia is moderately pronounced on the maxilla, and on the mandible it ranges from mild to moderate. The present jaw and dental arch anomalies are the distal rotation of teeth 34 (30°) and 35 (30°), as well as the dislocation of tooth 27 in place of tooth 26, lost ante-mortem. Caries was noted on the following teeth: 14 (distal, 0.5 cm in diameter), 15 (distal and mesial, so-called gross caries), 23 (distal, carious stain, 0.5 cm in diameter), 24 (mesial, 0.5 cm in diameter), 34 (mesial, 0.2 cm in diameter), 35 (distal, so-called gross caries), 36 (so-called gross-gross caries), 37 (mesial, between the crown and the root, 0.85 cm in

diameter), 38 (occlusal, 0.5 and 0.2 cm in diameter), 44 (distal, 0.1 cm in diameter), 45 (so-called gross-gross caries) and 46 (so-called gross-gross caries). Buccal cysts are present on teeth 35 (0.65 cm in diameter) and 46 (0.90 cm in diameter). Occlusion: tête-à-tête.

On the postcranial part of the skeleton, the epigenetic characteristic *facies articularis superior atlantis bipartite* was detected on the atlas.

Markers of occupational stress in the form of hypertrophy (cortical defect) are visible on the muscle and ligament attachment points of the mandible (*m. genioglossus*, *m. geniohyoideus*), manubrium (*m. sternocleidomastoideus*, *m. pectoralis major*, *lig. sternoclaviculare anterius*) (Plate IV/2), ribs (*Mm. levatores costarum*), both scapulae (*m. biceps brachii – Caput longum*, *m. triceps brachii – Caput longum*, *m. teres minor*, *m. infraspinitus*, *m. subscapularis*), right clavicle (*m. deltoideus*), right humerus (*m. supraspinatus*, *m. subscapularis*, *m. latissimus dorsi*, *m. teres major*, *m. pectoralis major*, *m. deltoideus*, *m. coracobrachialis*), left humerus (*m. deltoideus*, *m. coracobrachialis*) and right femur (all muscle attachment points are pronounced along the *lineae asperae*, *m. gastrocnemius – Caput mediale*, *m. adductor magnus*, *m. plantaris*, *m. gastrocnemius – Caput laterale*).

Other observations: On the tuberosity of the right tibia, brown coloured traces of metal oxidation are visible. The same traces are visible on the anterior side of the lower end of the right femur.

Grave 99

Sondage F II (VII)/1996.

Rectangular burial pit dug into the subsoil (green-yellowish marl), dimensions: 2.10 x 0.75 m, with bottom at a relative depth of 2.00 m.

Orientation: west-east.

Skeleton dislocated.

Finds:

1. an amphora-shaped bronze belt-end among the dislocated bones (Pl. III, 2),⁴⁹
2. fragments of bronze plating among the dislocated bones.

⁴⁸ Degree of bone preservation: category IV (partially preserved cranial and postcranial skeleton).

⁴⁹ Petković *et al.* 2005, 94, Cat. 1, Fig. 19 a, Pl. XI, G. 99, 1 – is dated to the second half of the 4th and the first half of the 5th century.

CRANIAL SKELETON	GRAVE 91	GRAVE 99
Mandible		
Mandibular Index	86.96	-
Mandibular Robustness Index	27.78	30.78
Mandibular Branch Index	44.52	47.14
Fronto–mandibular Index	90.38	-

Table 3. Indices on the cranial skeleton

Табела 3. Индекси на кранијалном скелету

Note: The grave was damaged by grave robbers.

ANTHROPOLOGICAL ANALYSIS:

In the grave, skeletal remains of an adult male individual, aged 30–35, were discovered.⁵⁰

The perceived paleopathological changes are a trace of an injury in the form of a shallow depression on the right femur (3.7 x 1 cm in size) and the appearance of *osteosarcoma* (?) – the bone is very decomposed and it is difficult to determine, with any certainty, precisely what type of tumour this is.

Dental analysis indicated the presence of the following teeth in the jaws: 23, 24, 25, 26, 35, 36, 37, 38, 42, 43, 45, 46, 47 and 48. Teeth 21, 22, 27, 28, 31, 32, 33, 34, 41 and 44 were lost post-mortem. Abrasion of the 1st degree (in enamel) was noted on teeth 24, 25 (→ 2nd), 35, 38, 45 and 48, and of the 2nd degree (exposed dentin) on teeth 23, 26, 36, 37, 42, 43, 46 and 47. Parodontopathy (maxilla and mandible) and calculus (mandible) are mildly pronounced. The present jaw and dental arch anomaly is the mesial rotation of tooth 24 (30°). Caries was not perceived. Occlusion could not be determined.

The noticeable epigenetic characteristics on the *norma occipitalis* are *ossa suturae lambdoideae* (five on the right side, of the following dimensions: 1.1 x 0.8 cm, 0.8 x 1.5 cm, 0.75 x 2 cm, 0.9 x 1.9 cm and 1.8 x 2.5 cm; the occipital bone was damaged post-mortem on its left side, however, it appears that the *ossa suturae lambdoideae* exist there as well).

Markers of occupational stress in the form of hypertrophy (cortical defect) are visible on the muscle attachment points of the right humerus (*m. supraspinatus*). Markers of occupational stress in the form of hypertrophy (cortical defect) are also visible on the ligament

attachment points of the right clavicle (*lig. conoideum*) and left clavicle (*lig. trapezoideum, lig. conoideum*).

Grave 141⁵¹

Sondage I/2012.

Freely dug burial pit. The dimensions and relative depth cannot be determined since the grave was damaged by erosion and grave robbers. Two iron nails next to the left upper arm and one below the left leg, testify to the existence of a wooden casket.

Orientation: southwest-northeast.

Skeleton dislocated, with head and right side of the body missing.

Finds:

1. rectangular silver belt plating, decorated longitudinally with an incised “waving spiral”, next to the left pelvic bone (Pl. II, 7),⁵²

2. a bronze coin of Constantine I, minted 326–328, next to the left foot,⁵³

3–4. 3 iron nails next to the left upper arm.

Note: The grave was destroyed by the erosion of the eastern slope of the Slog hill and by grave robbers.

ANTHROPOLOGICAL ANALYSIS:

In the grave, skeletal remains of an adult male (?) individual, of unknown age, were discovered.⁵⁴

⁵⁰ Degree of bone preservation: category IV (partially preserved cranial and postcranial skeleton).

⁵¹ Excluding grave 141, which was explored during the site survey in 2012, in the course of the 2013 rescue excavations, 16 more graves were discovered at the Slog necropolis, 7 of which were Late Roman (G. 143, G. 149–152, G. 154 and G. 157) – Петковић, Радиновић, Илијић 2014, 33–38. In 2014, more 31 graves were excavated (G. 159–188), among them at least 8 from the Late Roman period.

⁵² Rectangular silver plating of a belt set, with faceted narrower sides, decorated longitudinally with an incised “waving spiral”, was attached by two rivets onto the leather strap (dim: 2.5 x 0.8 cm). Generally, it can be dated to the second half of the 4th and the first half of the 5th century, and more specifically to the last third of the 4th and the first decade of the 5th century (Bullinger 1969, 47, Typ Furfooz, 58–59, Typ Abbeville, Abb. 16, 1, Abb. 36, 2, Abb. 42, 1, T. XXX, 2, T. LVI, T. LX, 1; Sommer 1984, 62–68, Gruppe 2–3, T. 46, 15.16, T. 58, 7–9; Nagy 2005, 450–456, T. Abb. 13, 7–18, Abb. 26–27).

⁵³ Obv: CONSTAN TINVS AVG, rev: PROVIDEN TIAEAVGG, a gate fortified with two turrets and a star between them, no door, mint-mark of Thessalonica SMTSA (RIC VII, 153).

⁵⁴ Degree of bone preservation: category IV (partially preserved cranial and postcranial skeleton).

POSTCRANIAL SKELETON	GRAVE 69A	GRAVE 79	GRAVE 91	GRAVE 99	GRAVE 141
Humerus					
Robusticity Index	-	-	-	-	-
	-	-	-	-	21.94
Cross-Section Index	-	-	75	72.34	-
	-	-	84.78	-	89.13
Radiohumeral Index	-	-	-	-	-
	-	-	-	-	72.58
Radius					
The Length-Thickness Index	-	-	-	-	-
	-	-	-	-	8.41
Cross-Section Index	-	-	-	-	-
	-	-	-	-	5.68
Femur					
Robusticity Index	-	-	12.34	-	-
	-	-	-	-	13.45
Pilastric Index	-	106.90	103.51	-	-
	-	110.34	-	-	105.26
Platymeric Index	-	-	-	-	-
	-	-	-	-	80.70
Tibia					
Platynemic Index	69.23 mesocn.	70.13 eurycn.	68 mesocn.	-	-
	-	71.43 eurycn.	-	-	68.83 mesocn.

Table 4. Indices on the postcranial skeleton

Табела 4. Индекси на постранијалном скелету

The perceived paleopathological change is *myositis ossificans traumatica* (2.5 x 8 cm in size), in the region of the *m. tibialis posterior* (on the middle of the body of the left tibia, on the posterior side) (Pl. IV, 4–7).

The epigenetic characteristic observed on the postcranial part of the skeleton is *perforatio fossae olecrani* (0.3 cm in diameter) on the left humerus.

Markers of occupational stress in the form of hypertrophy (cortical defect) are visible on the muscle attachments points of the left scapula (*m. triceps brachii* – *Caput longum*, *m. subscapularis*, *m. infraspinatus*, *m. teres minor*, *m. teres major*, *m. deltoideus*), left humerus (*m. subscapularis*, *m. pectoralis major*, *m. latissimus dorsi*, *m. teres major*, *m. deltoideus*, *m. coracobrachialis*), left radius (*m. biceps brachii*), left ulna (*m. supinator*, *m. brachialis*, *m. flexor digitorum superficialis*, *m. pronator teres*, *m. flexor carpi ulnaris*, *m. extensor carpi ulnaris*) and left femur (*m. adductor magnus*, *m. gastrocnemius* – *Caput mediale*). Markers of occupational stress in the form of hypertrophy (cortical defect) are also visible on the ligament attachment point of the left femur (*lig. capitis femoris*).

Other observations: On the 1st metacarpal bone, a trace of green coloured metal oxidation is visible. This kind of trace, considering that it is on a hand bone, could have been made by a part of the belt set.

PHASE II OF THE NECROPOLIS (380–410) (Pl. V)

Grave 15

Sondage F I/1994.

Rectangular burial pit dug into the subsoil (green-yellowish marl), dimensions: 1.80 x 0.80 m, above which there was a construction of broken stone and tegulae that was destroyed and dislocated next to the grave. Bottom at a relative depth of 1.20 m.

Orientation: west-east, with a deviation of 13° towards the north.

Skeleton dislocated.

No finds.

Note: The grave was robbed which resulted in the destruction of its stone construction.

INDIVIDUAL AGE	MALE		FEMALE		UNDETERMINED SEX		TOTAL	
juvenilis I (15-18 years)	-	-	-	-	-	-	-	-
juvenilis II (19-22 years)	-	-	-	-	-	-	-	-
adultus I (23-30 years)	1	1	-	-	-	-	1	1
adultus II (31-40 years)	4		-	-	-	-	4	
maturus I (41-50 years)	1	1	-	-	-	-	1	1
maturus II (51-60 years)	-		-	-	-	-	-	
senilis I (61-70 years)	-	-	-	-	-	-	-	-
senilis II (71 and more)	-		-	-	-	-	-	
unknown age	-		-		-		-	
TOTAL NUMBER OF JUVENILES AND ADULTS	8		-		-		8	
TOTAL NUMBER OF INDIVIDUALS	8		-		-		8	

Table 5. Sex and age structure of individuals

Табела 5. Полна и старосна структура индивида

ANTHROPOLOGICAL ANALYSIS:

In the grave, skeletal remains of an adult male individual, aged 35–45, were discovered.⁵⁵

The perceived paleopathological changes are traces of injuries in the form of two cuts on the frontal bone (Pl. VIII, 1–3). Both of them were probably inflicted by the sharp blade of a sword. One is in the region above the right orbit. Although it is a serious injury (the separated part of the bone is 2 x 1.7 cm in size, and the cut is 0.4 cm deep), traces of healing are clearly visible in the picture (Pl. VIII, 3). The second injury is above the left orbit, also with traces of healing. The injuries were inflicted in a direct clash by a right-handed opponent. Other noticeable paleopathological changes are a fused fissure on the *malleolus medialis* of the right tibia, spondylolysis (on the atlas), osteoarthritis (on the right glenoid cavity and vertebrae L1, L2, L4 and L5, on the olecranon of the left ulna, the 1st right metacarpal bone, the pelvic bones, the right patella and on the lower tibia ends), *spondylarthrosis* (of the second degree on C4, C6 and C7), osteoporosis (on the promontorium, and the thoracic and lumbar vertebrae) and *osteochondritis dissecans* (near the upper end on the anterior side of the left femur, 0.5 cm in diameter).

Dental analysis indicated the presence of the following teeth in the jaws: 12, 13, 16, 17, 22, 23, 24, 25, 26, 32, 33, 34, 35, 36, 37, 41, 42, 43, 44, 45, 46, 47 and 48. Teeth 11, 14, 15, 21, 31 and 38 were lost post-mortem. Abrasion of the 1st degree (in enamel) was noted on tooth 48, of the 3rd degree (to the bottom of the fissure) on teeth 12, 13 (→ 4th), 16 (→ 4th), 17, 32,

33, 34, 35, 37, 42, 43, 44, 45 and 47, and of the 4th degree (pulp exposure) on teeth 22, 23, 24, 25, 26, 36, 41 and 46. On maxillary teeth, hypoplasia is mildly pronounced and parodontopathy is very pronounced. On the mandibular teeth, hypoplasia and parodontopathy are moderately pronounced, and calculus mildly to moderately pronounced. Occlusion: tête-à-tête.

The noticeable epigenetic characteristic on the *norma lateralis* is *os incisurae parietalis* (on the left side 0.75 x 1.20 cm). On the postcranial part of the skeleton, *facies articularis superior atlantis bipartite* (on the left side) and *trochanter tertius* (on the left femur) were observed.

Markers of occupational stress in the form of hypertrophy (cortical defect) are visible on the muscle attachment points of the ribs (*Mm. levatores costarum*), both clavicles (*m. trapezius*, *m. deltoideus*, *m. pectoralis major*, *m. sternocleidomastoideus*, *m. subclavius*), left humerus (*m. deltoideus*, *m. coracobrachialis*, *m. brachialis*), left ulna (*m. flexor digitorum superficialis*, *m. pronator teres*, *m. brachialis*, *m. supinator*), left radius (*m. flexor digitorum superficialis*), right and left tibia (*m. quadriceps femoris*, *m. solei*) and both femurs (*m. gastrocnemius – Caput mediale*, *m. adductor magnus*, *m. plantaris*, *m. gastrocnemius – Caput laterale*, *m. popliteus*, *m. biceps femoris – Caput breve*, *m. adductor brevis*, *m. vastus intermedius*, *m. vastus medialis*, *m.*

⁵⁵ Degree of bone preservation: category III (moderately preserved cranial and postcranial skeleton).

STATURE (cm)	GRAVE 15	GRAVE 25	GRAVE 26	GRAVE 76	GRAVE 123
humerus	-	-	-	181 ± 5	-
radius	-	-	-	178 ± 5	-
ulna	170 ± 5	-	-	183 ± 5	-
femur	167 ± 4	-	-	-	171 ± 4
tibia	168 ± 4	165 ± 4	166 ± 4	-	-
fibula	-	-	-	-	-
medium	168 ± 4	165 ± 4	166 ± 4	181 ± 5	171 ± 4

Table 6. Stature

Табела 6. Телесна висина

adductor magnus, m. vastus lateralis). Markers of occupational stress in the form of hypertrophy (cortical defect) are also visible on the ligament attachment points of both clavicles (*lig. trapezoideum, lig. conoideum, lig. costoclaviculare*), manubrium (*lig. sternoclaviculare posterius*) and both femurs (*lig. capitis femoris, lig. cruciatum posterius, lig. cruciatum anterius*). Both clavicles exhibit a flattening of the body (direction: *superior-inferior*) (Pl. VIII, 4). The *incisura clavicularis* on the manubrium is perceptibly extended to the left side (Pl. VIII, 5–6). The olecranon of the left ulna is slightly separated, and the *margo interosseus* is mildly pronounced. The *margo interosseus* of the left radius is also pronounced.

Grave 25

Sondage F I/1994.

Grave construction made of river pebbles, preserved on both sides of the head, below the feet and along the right side of the skeleton. The bottom of the pit at a relative depth of 1.10 m.

Orientation: west-east, with a 3° deviation towards the south.

Skeleton supine with legs extended, arms bent at elbows and hands on pelvis.

Finds (Pl. VII, 1):

1. 32 decorative (?) iron rivets with pyramidal heads, from shoes or belt,

2. a frame of an iron buckle in the form of the Latin letter B, near the feet (Pl. VI, 1).⁵⁶

Note: The grave construction was destroyed by the digging of the medieval grave 6.

ANTHROPOLOGICAL ANALYSIS:

In the grave, skeletal remains of an adult male individual, aged 20–25, were discovered.⁵⁷

The perceived paleopathological changes are *spina bifida occulta* on the sacrum, osteoarthritis (on both calcanei) and a bony growth (osteoma?), right of the mentum (about 1 cm in diameter).

Dental analysis indicated the presence of the following teeth in the jaws: 12, 13, 14, 15, 16, 17, 21, 23, 24 (root), 25, 26, 27, 31, 32, 33, 34, 37, 38, 41, 42, 43, 44, 45 and 48. Teeth 36, 46 and 47 were lost ante-mortem, and tooth 35 post-mortem. Abrasion of the 1st degree (in enamel) was noted on teeth 15, 16, 25, 26, 27 and 37, of the 2nd degree (exposed dentin) on teeth 12 (→3rd), 17, 23, 32, 34, 42, 44 and 45, and of the 3rd degree (to the bottom of the fissure) on teeth 13, 14, 21 (→4th), 31, 33, 41 and 43. Parodontopathy is very pronounced on the maxilla. On the mandible, parodontopathy ranges from moderately to very pronounced. Calculus is moderately pronounced on the mandibular teeth. Hypoplasia is moderately pronounced on the maxillary and mandibular teeth. The present jaw and dental arch anomaly is the mesial rotation of teeth 31 (30°) and 41 (30°). A cyst is visible on the buccal side of tooth 47 (1 cm in diameter). Occlusion could not be determined.

Markers of occupational stress in the form of hypertrophy (cortical defect) are visible on the muscle attachment points of the ribs (*Mm. levatores costarum*), both humeri (*m. deltoideus, m. coracobrachialis, m.*

⁵⁶ Petković *et al.* 2005, 91, Cat. 3, Fig. 18 c, Pl. III, G. 25, 1 – is dated to the last quarter of the 4th and the first half of the 5th century.

⁵⁷ Degree of bone preservation: category III (moderately preserved cranial and postcranial skeleton).

brachialis), right ulna (*m. brachialis*) and right radius (*m. extensor digiti minimi*, *m. extensor indicis*, *m. extensor pollicis longus*, *m. extensor carpi radialis brevis*, *m. extensor carpi radialis longus*, *m. abductor pollicis longus*, *m. extensor pollicis brevis*). Markers of occupational stress in the form of hypertrophy (cortical defect), 1.8 x 0.9 cm and 1.4 x 0.70 cm in size, are visible on the ligament attachment points of both clavicles (*lig. costoclaviculare*) (Pl. IX, 1).

Grave 26

Sondage F I/1994.

Destroyed grave construction of river pebbles above the rectangular burial pit, with bottom at a relative depth of 1.00 m. Finds of nails, below the legs and along the left side of the skeleton, indicate the existence of a wooden casket.

Orientation: west-east, with a 4° deviation towards the south.

Skeleton supine with legs extended, arms bent at elbows and hands on pelvis.

Finds (Pl. VII, 2):

1. a bronze consecration coin of Constantine I from 341–346 and two bronze coins of Constans, minted 341–348, to the left of the skull,⁵⁸

2. a bronze buckle in the region of the pelvis,⁵⁹

3. an amphora-shaped bronze belt-end in the region of the pelvis,⁶⁰

4. a small, olive green glazed ceramic vessel with three handles, next to the right foot (Pl. VI, 2).⁶¹

Note: It is situated above the Late Roman grave 44. The coin finds from this grave might belong to the inventory of grave 44.

ANTHROPOLOGICAL ANALYSIS:

In the grave, skeletal remains of an adult male individual, aged 20–40, were discovered.⁶²

The perceived paleopathological change is a trace of an injury on the left *processus zygomaticus*, 2 x 1 cm in size (Pl. IX, 2). The injury was most probably inflicted in a direct clash by a right-handed individual with a blunt object. Other noticeable paleopathological changes are osteoarthritis (on calcanei), defect in the joint of the right ankle and *spondyloarthrosis* of the second degree on C3 and C4.

The noticeable epigenetic characteristics on the *norma lateralis* are two *foramen zygomaticofaciale* (on the right zygomatic bone).

Dental analysis indicated the presence of the following teeth in the jaws: 11, 12, 13, 14, 15, 16, 17, 21, 22, 23, 24, 25, 31 (?), 32, 33, 34, 38, 42, 44, root (35 or 45) and 48 (root). Abrasion of the 1st degree (in enamel) was noted on teeth 16, 17, 24, 25, 33 and 34 (→2nd), of the 2nd degree (exposed dentin) on teeth 14 (→3rd), 15, 22 and 23, of the 3rd degree (to the bottom of the fissure) on teeth 13, 21, 31 (?), 32, 42 and 44, and of the 4th degree (pulp exposure), on teeth 11 and 12. Parodontopathy is very pronounced on the maxilla and mandible. Hypoplasia and calculus are mildly pronounced. Decolourisation of the enamel is visible on the labial side of teeth 11 and 12. The present jaw and dental arch anomalies are the mesial rotation of teeth 11 and 21 (30°) and the distal rotation of tooth 15 (30°). Caries was noted on teeth 12 (distal, 0.3 cm in diameter and mesial, 0.1 cm in diameter), 13 (mesial, 0.4 cm in diameter), 15 (distal, 0.6 cm in diameter), 16 (lingual, so-called gross caries and buccal, 0.5 cm in diameter), 17 (buccal, 0.5 cm in diameter), 23 (mesial, caries (?), 0.2 cm in diameter), 24 (mesial, 0.4 cm in diameter), 25 (mesial, between the crown and the root, 0.5 cm in diameter), 37 (occlusal/mesial, 0.7 cm in diameter), 38 (distal, between the crown and the root, 0.65 cm in diameter) and 48 (so-called gross-gross caries). A cyst exists on the buccal side of tooth 24 (0.4 cm in diameter). Occlusion could not be determined.

Grave 27A

Sondage F I/1994.

Destroyed rectangular construction of river pebbles above a burial pit, dimensions: 1.80 x 0.90 m, with bottom at a relative depth of 1.70 m.

Orientation: west-east, with a 7° deviation towards the south.

Skeleton dislocated.

⁵⁸ Petković *et al.* 2005, 115, 117, Cat. 5, 16–17.

⁵⁹ The shape of the bronze belt buckle could not be determined, since it was destroyed in conservation process.

⁶⁰ Petković *et al.* 2005, 93–94, Cat. 2, Pl. IV, G. 26, 3 – is dated to the second half of the 4th and the 1st half of the 5th century.

⁶¹ Petković *et al.* 2005, 111, Cat. 3, Fig. 21, type III/1, Pl. 9, 5; Цвијетићанин 2006, 87, КАГ 146; Jeremić 2009, 93, Type II/9, Fig. 51, Cat. 249–250, 252 – is dated to the 3rd and 4th century.

⁶² Degree of bone preservation: category III (moderately preserved cranial and postcranial skeleton).

⁶³ Petković *et al.* 2005, 89–90, 92, Fig. 18d, Pl. 10, 4, Cat. 6 – is dated to the last quarter of the 4th and the beginning of 5th century.

- Finds (Pl. VII, 3):
1. a bronze buckle with a rectangular plate and a circular frame among the dislocated bones (Pl. VI, 3),⁶³
 2. a bronze loop among the dislocated bones,
 3. a conical shank of a leaf-shaped iron arrowhead among the dislocated bones.

Table 7. Indices on the cranial skeleton

Табела 7. Индекси на кранијалном скелету

CRANIAL SKELETON	GRAVE 15	GRAVE 25	GRAVE 28	GRAVE 76	GRAVE 123
Primary cranial measures					
Cranial Index	81.46 brachycranic	-	82.02 brachycranic	75.92 mesocranic	-
Cranial Length-Height Index	76.40 hypsicranic	-	-	-	-
Cranial Breadth-Height Index	93.79 metriocranic	-	-	-	-
Mean Height Index	84.21 high	-	-	-	-
Cranial Module	15.30	-	-	-	-
Mean Porion-Height Index	74.30 high	-	-	73.81 high	-
Index of Flatness of the Cranial Base	5.88	-	-	-	-
Fronto-Parietal Index	66.9 metriometopic	-	69.86 metriometopic	64.14 stenometopic	-
Facial Skeleton					
Upper facial Index	-	-	49.28 euryenic	-	-
The Nose					
Nasal Index	-	-	48.08 leptorrhinic	-	-
The Orbits					
Orbital Index	-	-	- 79.49 chamaeconchic	-	-
Maxilla					
Maxilloalveolar Index	-	-	103.92 dolichuranic	-	-
The Palate					
Palatal Index	-	-	78.35 leptostaphilinic	-	-
Mandible					
Mandibular Index	88	-	-	94.02	-
Mandibular Robustness Index	41.27	52.38	-	33.90	42.86
Mandibular Branch Index	55.56	40.15	-	46.21	-
Fronto-mandibular Index	85.09	-	-	-	-

Note: The stone construction of the grave was destroyed by grave robbers. It is situated above the Late Roman grave 44.

ANTHROPOLOGICAL ANALYSIS:

In the grave, skeletal remains of an adult male (?) individual, aged 30–35, were discovered.⁶⁴

Paleopathological changes were not noticed.

Dental analysis indicated the presence of the following teeth in the jaws: 11, 14, 15, 16, 17, 18, 21, 23, 24, 25, 26, 27, 28, 32, 33, 34, 36, 37, 38, 43, 44, 45, 46, 47 and 48. Abrasion of the 1st degree (in enamel) was noted on teeth 17, 18, 27 (→2nd), 28, 34, 37, 38, 44 (→2nd), 47 and 48, and of the 2nd degree (exposed dentin) on teeth 11, 14, 15, 16, 21, 23, 24, 25, 26, 32, 33, 36, 43, 45 and 46. Hypoplasia is mildly pronounced on the maxillary and mandibular teeth. Caries was noted on teeth 16 (buccal, 0.45 cm in diameter), 18 (occlusal, in the form of a dot) and 14 (distal, 0.3 cm in diameter). Occlusion could not be determined.

Grave 28

Sondage F III/1994.

Destroyed grave construction of river pebbles above a burial pit, with bottom at a relative depth of 1.75 m.

Orientation: west-east, with a 2° deviation towards the south.

Skeleton supine with legs extended, arms bent at elbows, and hands on pelvis. The skull was found in the region of the stomach.

Finds:

1. a frame of an iron buckle in the shape of the Latin letter B, on the right pelvic bone (Pl. VII, 4).⁶⁵

Note: The grave was robbed and on that occasion the grave construction was destroyed.

ANTHROPOLOGICAL FINDS:

In the grave, skeletal remains of an adult male individual, aged 30–40 (dental age 30–35), were discovered.⁶⁶

The only paleopathological change detected is scurvy (changes are visible on the roofs of the orbits, zygomatic bones, the palatine bone, temporal bones and on bones of the skull base).

The noticeable epigenetic characteristics on the *norma frontalis* are openings and notches in the supra-orbital region and a partially fused metopic suture (*sutura metopica*).

Dental analysis indicated the presence of the following teeth in the jaws: 12, 13, 14, 15, 18, 25, 28, 32, 33, 43 and 48. Teeth 16, 17, 26 and 27 were lost ante-mortem, and teeth 11, 21, 22, 23, 24, 31, 34, 35, 36, 37 and 38, post-mortem. Abrasion of the 1st degree (in enamel) was detected on teeth 18, 28 (→2nd) and 48, of the 2nd degree (exposed dentin) on teeth 32, 33 and 43, of the 3rd degree (to the bottom of the fissure) on teeth 13, 14 and 15, and of the 4th degree (pulp exposure) on teeth 12 and 25. Parodontopathy is moderately pronounced on the maxilla. Hypoplasia is mildly pronounced on the maxillary and mandibular teeth. The present jaw and dental arch anomaly is the distal rotation of teeth 14 (30°) and 24 (30°). Caries was noted on tooth 48 (occlusal, 0.15 cm in diameter). A periapical cystic cavity is visible on the buccal side of tooth 24 (0.65 cm in diameter). Occlusion could not be determined.

Other observations: Batricephalia is present on the occipital bone.

Grave 76

Sondage III/1995.

Freely dug burial pit, with bottom at a relative depth of 1.00 m.

Orientation: west-east, with a 40° deviation towards the south.

Skeleton supine with legs extended and arms straight, placed alongside the body.

Finds:

1. a conical glass goblet next to the right foot (Pl. VI, 4).⁶⁷

ANTHROPOLOGICAL ANALYSIS:

In the grave, skeletal remains of an adult male individual, aged 40–50, were discovered.⁶⁸

⁶⁴ Degree of bone preservation: category V (poorly preserved postcranial skeleton). In the same grave the remains of the poorly preserved dental material (category V) of a child, aged 10 years ± 30 months, of unknown sex, were discovered (Grave 27B).

⁶⁵ See note no. 55.

⁶⁶ Degree of bone preservation: category IV (partially preserved cranial and postcranial skeleton).

⁶⁷ Ružić 1994, 50–52, tip VII/12 b, T. XXXVIII, 12 – is dated to the second half of the 4th and the first half of the 5th century.

⁶⁸ Degree of bone preservation: category III (moderately preserved cranial and postcranial skeleton).

The perceived paleopathological change is scurvy (changes are visible on the roofs of the orbits, the palatine bone, the mandibular condyles and on the wings of the sphenoid bone).⁶⁹ Other noticeable paleopathological changes are a fused fracture of the head of the right femur (Pl. IX, 3), subperiosteal hematoma (in the lower half of the body of the left fibula on the *facies medialis*), superiosteal hematoma (on the medial side of the right femur throughout the whole length of the body), anomalies in the skeletal development (*bipartite* right patella) and dislocation of the disk in thoracic vertebrae.

Dental analysis indicated the presence of the following teeth in the jaws: 11, 13, 14, 16 (root), 17, 18, 21, 22, 23, 24, 26 (root), 31, 32, 33, 34, 35, 36, 37, 38, 41, 42, 43, 44, 45, 46, 47 and 48. Teeth 12, 15 and 25 were lost post-mortem. Abrasion of the 1st degree (in enamel) was noted on teeth 18, 24 and 34, of the 2nd degree (exposed dentin) on teeth 13, 21, 22, 32, 33, 38, 44 and 48, of the 3rd degree (to the bottom of the fissure) on teeth 11 (→4th), 14, 17, 23 (→4th), 35, 37 (→4th), 42, 43, 45 and 47 (→4th), and of the 4th degree (pulp exposure) on teeth 31, 36, 41 and 46. On the maxillary teeth, hypoplasia is mildly to moderately pronounced, and parodontopathy moderately to very pronounced. On the mandibular teeth, hypoplasia is mildly pronounced, and parodontopathy mildly to moderately pronounced. The present jaw and dental arch anomalies are the mesial rotation of teeth 33 (30°) and 43 (45°), as well as the retrusion of teeth 22, 32, 42 and 45 towards the lingual side. Caries was noted on teeth 16 (so-called gross-gross caries) and 26 (so-called gross-gross caries). Periapical cystic cavities are visible on the buccal side of teeth 16 (0.6 cm in diameter) and 26 (0.8 cm in diameter). Fenestration (0.4 x 0.7 cm in size) is present on the buccal side of tooth 25. Occlusion: tête-à-tête.

The detected epigenetic characteristic on the postcranial part of the skeleton is *trochanter tertius* on the left femur.

Markers of occupational stress in the form of hypertrophy (cortical defect) are visible on the muscle attachment points of the ribs (*Mm. levatores costarum*), right and left clavicle (*m. deltoideus*), right and left scapula (*m. deltoideus*, *m. biceps brachii – Caput longum*, *m. biceps brachii – Caput breve*, *m. triceps brachii – Caput longum*, *m. subscapularis*, *m. infraspinatus*, *m. teres minor*, *m. teres major*), right humerus (*m. subscapularis*, *m. latissimus dorsi*, *m. teres major*, *m. pectoralis major*, *m. deltoideus*, *m. coracobrachialis*, *m. brachialis*, *m. brachioradialis*, *m. extensor carpi radialis longus*,

POSTCRANIAL SKELETON	GRAVE 25	GRAVE 76
Scapula		
Scapular Indeks	-	70.97
Clavicle	-	-
Clavicle		
Claviculohumeral Index	-	43.66
Robustness Index	-	43.18
Robustness Index	28	22.58
	-	24.34

Table 8. Indices on the postcranial skeleton

Табела 8. Индекси на пошћкранијалном скелету

m. extensor carpi radialis brevis, *m. pronator teres*, *m. extensor digitorum*, *m. extensor digiti minimi*, *m. extensor carpi ulnaris*, *m. supinator*, *m. flexor carpi radialis*, *m. palmaris longus*, *m. flexor carpi ulnaris*, *m. flexor digitorum superficialis*), left humerus (*m. latissimus dorsi*, *m. teres major*, *m. pectoralis major*, *m. deltoideus*, *m. coracobrachialis*, *m. brachialis*, *m. brachioradialis*, *m. extensor carpi radialis longus*, *m. extensor carpi radialis brevis*, *m. pronator teres*, *m. extensor digitorum*, *m. extensor digiti minimi*, *m. extensor carpi ulnaris*, *m. supinator*, *m. flexor carpi radialis*, *m. palmaris longus*, *m. flexor carpi ulnaris*, *m. flexor digitorum superficialis*), right and left ulna (*m. flexor digitorum superficialis*, *m. pronator teres*, *m. brachialis*, *m. supinator*, *m. pronator quadratus* (on the left ulna it created a sulcus: 0.5 cm in width, 3.6 cm in length and 0.03 cm in depth), *m. triceps brachii*, *m. flexor carpi ulnaris*), right radius (*m. biceps brachii*, *m. abductor pollicis longus*, *m. extensor pollicis brevis*, *m. pronator teres*, *m. extensor digiti minimi*, *m. extensor digitorum*, *m. extensor indicis*, *m. extensor pollicis longus*, *m. extensor carpi radialis brevis*, *m. extensor carpi radialis longus*, *m. abductor pollicis longus*), left radius (*m. biceps brachii*, *m. abductor pollicis longus*, *m. extensor pollicis brevis*, *m. pronator teres*), right and left femur (*m. iliopsoas*, *m. adductor magnus*, *m. gluteus maximus*, *m. vastus lateralis*, *m. pectineus*, *m. vastus medialis*, *m. adductor brevis*, *m. vastus intermedius*, *m. adductor longus*, *m. biceps femoris – Caput breve*). The olecranon of both

⁶⁹ Scurvy appears as a consequence of the deficiency of vitamin C in the diet. It is common in times of drought or war, when the diet is unvaried and fruit and vegetable intake is reduced.

ulnas are slightly separated. The *corpus sterni* is slightly curved to the left side. The spina and acromion of both scapulae are deformed. The *corpus costae* of seven fragmented ribs have a more pronounced curvature than usual (near the *facies articularis tuberculi costae*).

Grave 97

Sondage F II (VII)/1995.

Remains of a stone construction around the skull. The bottom of the burial pit at a relative depth of 2.00 m.

Orientation: west-east.

Skeleton supine with legs extended.

Finds (Pl. VII, 5):

1. a shank of an iron spear to the right of the skull,⁷⁰

2. a leaf-shaped iron arrowhead in the region of the right pelvic bone,⁷¹

3. an animal bone (sheep or goat's pelvic bone) in the region of the chest.

Note: The grave was probably robbed, since the leg bones were dislocated.

ANTHROPOLOGICAL ANALYSIS:

In the grave, skeletal remains of an adult male individual, aged around 40, were discovered.⁷²

The only paleopathological change detected is osteoarthritis (on the tuberosity of the left tibia, on both tali and both calcanei).

Dental analysis indicated the presence of the following teeth in the jaws: 12, 13, 21, 24, 25, 41, 43, 46 and 47. Abrasion of the 1st degree (in enamel) was noted

Table 9. Indices on the postcranial skeleton

Табела 9. Индекси на постранијалном скелету

POSTCRANIAL SKELETON	GRAVE 15	GRAVE 25	GRAVE 26	GRAVE 27A	GRAVE 28	GRAVE 76	GRAVE 97	GRAVE 123
Humerus								
Robusticity Index	-	-	-	-	-	17.18	-	-
	-	-	-	-	-	17.90	-	-
Cross-Section Index	76.09	76.19	-	-	-	77.78	92.10	-
	71.70	75.61	-	-	-	82.93	-	-
Radiohumeral Index	-	-	-	-	-	73.24	-	-
	-	-	-	-	-	73.86	-	-
Radius								
The Length-Thickness Index	-	-	-	-	-	16.94	-	-
	-	-	-	-	-	16.19	-	-
Cross-Section Index	-	-	-	-	-	4.84	-	-
	-	-	-	-	-	4.66	-	-
The Length-Breadth Index	-	-	-	-	-	14.11	-	-
	-	-	-	-	-	-	-	-
Ulna								
Caliber Index	-	16.36	-	-	-	14.17	-	-
	17.76	-	-	-	-	-	-	-
Femur								
Robusticity Index	13.93	-	-	-	-	-	-	13.13
	14.81	-	-	-	-	-	-	12.72
Pilastric Index	120.37	-	-	100	-	93.55	107.02	95.08
	122.22	-	-	91.07	-	85.71	105.45	100
Platymetric Index	93.33 eury. 103.23 sten.	-	-	76.93 platy. 70.59 platy.	-	69.33 platym. 75.64 platym.	87.50 eury. 80.88 platym.	77.61 platy. 87.69 eury.
Tibia								
The Length-Breadth Index	22.60	20.41	-	-	-	-	-	-
	-	-	20.98	-	-	-	-	-
Platynemic Index	80.30 euryc. 80.60 euryc.	65.15 meso. -	-	-	66.67 mesoc. -	-	-	-
	-	-	68.57 mesoc.	-	-	-	74.63 eurycn.	-

on teeth 12, 13 (→2nd), 24, 25 and 43, of the 2nd degree (exposed dentin) on tooth 47, and of the 3rd degree (to the bottom of the fissure) on teeth 21, 41 and 46. Hypoplasia is moderately pronounced on the maxillary and mandibular teeth. Occlusion could not be determined.

Markers of occupational stress in the form of hypertrophy (cortical defect) are visible on the muscle attachment points of the right humerus (*m. deltoideus*, *m. brachialis*, *m. coracobrachialis*), left humerus (*m. deltoideus*) and both femurs (*m. gastrocnemius – Caput mediale*).

Grave 123

Sondage F I (VII)/1996.

Freely dug burial pit, with bottom at a relative depth of 1.20 m.

Orientation: west-east, with a 7° deviation towards the north.

Skeleton supine with legs extended, arms bent at elbows and hands crossed on the stomach. The bones of the lower leg and the feet are missing.

Finds (Pl. VII, 6):

1. an iron tri-bladed arrowhead between the ribs on the right side of the chest cavity (Pl. VI, 5),⁷³

2. a bronze buckle with an oval plate and an oval frame in the region of the pelvis.⁷⁴

Note: It is positioned below the Late Roman grave 102, which damaged it. The iron arrowhead does not represent a grave offering, and the place where it was found indicates the possible cause of death of the deceased.

ANTHROPOLOGICAL ANALYSIS:

In the grave, skeletal remains of an adult male individual, aged 45–65, were discovered.⁷⁵

The perceived paleopathological changes are traces of the healing of an injury in the region of the right asterion, *spondyloarthrosis* (of the 1st degree on T11 and T12, and the 3rd degree on T9 and T10), Schmorl's node (on T10) and a defect in the sacroiliac joints.

Dental analysis indicated the presence of the following teeth in the jaws: 11, 12, 13, 14, 15, 16, 21, 22, 23, 24, 25, 26, 28, 31, 32, 33, 34, 35 (root?), 36 (root?), 37, 41, 42, 43, 45, 47 and 48. Teeth 17, 18, 44 and 46 were lost ante-mortem, and tooth 38 post-mortem. Abrasion of the 2nd degree (exposed dentin) was noted on teeth 13, 14, 15, 23 (→3rd), 24 and 25, of the 2nd–3rd degree on teeth 31, 32, 33, 34, 35, 37, 41, 42, 43 and

48, of the 3rd degree (to the bottom of the fissure) on teeth 11, 12, 16, 21, 22 and 26, and of the 4th degree (pulp exposure) on tooth 28. On the maxillary teeth, hypoplasia is mildly to moderately pronounced and parodontopathy moderately to very pronounced. On the mandibular teeth, both hypoplasia and parodontopathy are moderately pronounced. Calculus is mildly pronounced on both maxillary and mandibular teeth. The present jaw and dental arch anomaly is the mesial rotation of teeth 31 (30°) and 41 (30°). Decolourisation of the enamel is visible on teeth 16 (buccal), 21 (labial), 23 (labial) and 24 (labial). Caries was noted on teeth: 16 (distal, 0.3 cm in diameter), 22 (distal, carious stain, 0.25 cm in diameter), 23 (mesial, carious stain, 0.2 cm in diameter), 24 (occlusal, 0.2 cm in diameter), 26 (buccal, carious stain, 0.35 cm in diameter), 37 (distal, so-called gross caries), 45 (distal, carious stain, 0.25 cm in diameter) and 47 (mesial, 0.35 cm in diameter). A cyst, 2.1 x 1.4 cm in size, was noted buccally on teeth 17 and 18. On the buccal side of the crowns of teeth 15 and 25, vertical furrows are visible (0.4 cm in length, 0.35 cm in width and 0.05–0.1 cm in depth). Occlusion could not be determined.

Markers of occupational stress in the form of hypertrophy (cortical defect) are visible on the muscle attachment points of the right and left clavicle (*m. subclavius*), left scapula (*m. triceps brachii – Caput longum*), right and left humerus (*m. subscapularis*, *m. triceps brachii – Caput mediale*), right and left ulna (*m. brachialis*, *m. triceps brachii*, *m. flexor digitorum profundus*, *m. flexor carpi ulnaris*, *m. anconeus*), right radius (*m. supinator*, *m. flexor digitorum superficialis*), left radius (*m. biceps brachii*, *m. supinator*, *m. flexor digitorum superficialis*), right and left femur (all muscle attachment points are pronounced along the *linea asperae*). Markers of occupational stress in the form of hypertrophy (cortical defect) are visible on the ligament

⁷⁰ Petković *et al.* 2005, 100–101, Cat. 2, Pl. X, G. 97, 2.

⁷¹ Petković *et al.* 2005, 100–101, Cat. 4, Pl. X, G. 97, 1 – arrow type characteristic of the 3rd and the 4th century.

⁷² Degree of bone preservation: category IV (partially preserved cranial and postcranial skeleton).

⁷³ Petković *et al.* 2005, 100–101, Cat. 3, Pl. XI, G. 123, 1 – arrow type characteristic of the end of the 4th and the 5th century.

⁷⁴ Petković *et al.* 2005, 88, Fig. 18 a, Cat. 1, Pl. XI, G. 123, 2 – is dated to the second half of the 4th and the beginning of the 5th century.

⁷⁵ Degree of bone preservation: category IV (partially preserved cranial and postcranial skeleton).

attachment point of the left femur (*lig. capitis femoris*), and on the ligaments of both clavicles (*lig. trapezoideum*, *lig. conoideum*, *lig. costoclaviculare*).

Special observations: In the course of the excavation of the skeleton, among the ribs, on the right side, an arrowhead was found. A tri-bladed iron arrowhead in the chest cavity undoubtedly speaks to the cause of death of this person. Unfortunately, on the partially preserved rib fragments, no traces of injury were detected.

PHASE III OF THE NECROPOLIS (410–450) (Pl. X)

Grave 100

Sondage F I (VII)/1996.

Destroyed grave construction of stone and brick joined with mortar, with bottom at a relative depth of 0.70 m.

Orientation: west-east.

Skeleton dislocated.

Finds:

1. an atypical fragment of a glass goblet among the dislocated bones,
2. two atypical fragments of a ceramic lamp among the dislocated bones.

Note: The grave was destroyed by grave robbers.

ANTHROPOLOGICAL ANALYSIS:

In the grave, skeletal remains of an adult male individual, aged 40–50, were discovered.⁷⁶

The perceived paleopathological changes are an irregularly fused fracture of the right fibula in the upper quarter of its body (Pl. XI, 1–2), a trace of a subperiosteal hematoma near the upper end of the right tibia (on the lateral side), osteoarthritis (on the head of the right femur, on the tuberosity of the right tibia and on both calcanei), irregularly fused fracture of the neck of the right femur and a fracture of one rib, accompanied by osteomyelitis.

Dental analysis indicated the presence of the following teeth in the jaws: 11, 13, 14, 25, 31, 32, 33, 34, 36, 37, 41, 42, 43, 44 and 47. Teeth 35, 45 and 46 were lost post-mortem. Abrasion of the 1st degree (in enamel) was noted on tooth 47 (→2nd), of the 2nd degree (exposed dentin) on teeth 31, 32, 34 and 44, of the 3rd degree (to the bottom of the fissure) on teeth 11, 13, 25 (→4th), 33, 37 (→4th), 41 (→4th), 42 and 43, and of the 4th degree (pulp exposure) on teeth 14 and 36. On

the mandible, parodontopathy is very pronounced and calculus moderately pronounced. Hypoplasia is very pronounced on both the maxillary and mandibular teeth. A jaw and dental arch anomaly of hypodontia of teeth 38 and 48 is present. Caries was noted on teeth: 11 (distal, 0.3 cm in diameter) and 14 (distal, between the crown and the root, 0.5 cm in diameter). Occlusion could not be determined.

The perceived epigenetic characteristic on the *norma occipitalis* is a mildly pronounced *linea nuchae suprema*.

Markers of occupational stress in the form of hypertrophy (cortical defect) are visible on the muscle attachment points of the ribs (*Mm. levatores costarum*), right humerus (*m. deltoideus*, *m. brachioradialis*, *m. brachialis*, *m. coracobrachialis*, *m. pronator teres*, *m. triceps brachii* – *Caput laterale*), left humerus (*m. supraspinatus*, *m. subscapularis*, *m. latissimus dorsi*, *m. teres major*, *m. pectoralis major*, *m. deltoideus*, *m. coracobrachialis*, *m. brachioradialis*, *m. extensor carpi radialis longus*, *m. extensor carpi radialis brevis*) and left ulna (*m. supinator*, *m. brachialis*, *m. pronator teres*, *m. flexor digitorum superficialis*, *m. pronator quadratus*, *m. triceps brachii*, *m. flexor carpi ulnaris*, *m. extensor carpi ulnaris*). Markers of occupational stress in the form of hypertrophy (cortical defect) are also visible on the ligament attachment points of the left clavicle (*lig. trapezoideum*, *lig. conoideum*) and right femur (*lig. capitis femoris*).

Grave 102

Sondage F I (VII)/1996.

Destroyed rectangular grave construction of river pebbles and bricks, with bottom at a relative depth of 1.00 m.

Orientation: west-east, with a 5° deviation towards the north.

Skeleton supine with legs extended, upper part of skeleton dislocated.

Finds:

1. an iron buckle with a circular frame in the region of the pelvis (Pl. VII, 7).⁷⁷

⁷⁶ Degree of bone preservation: category IV (partially preserved cranial and postcranial skeleton).

⁷⁷ Petković *et al.* 2005, Fig. 18 e, 90, 92, Cat. 7 – is dated to the second half of the 4th and the first half of the 5th century.

INDIVIDUAL AGE	MALE		FEMALE		UNDETERMINED SEX		TOTAL	
juvenilis I (15-18 years)	-	-	-	-	-	-	-	-
juvenilis II (19-22 years)	1	-	-	-	-	-	1	-
adultus I (23-30 years)	-	-	-	-	-	-	-	-
adultus II (31-40 years)	-	-	-	-	-	-	-	-
maturus I (41-50 years)	2	-	-	-	-	-	2	-
maturus II (51-60 years)	-	-	-	-	-	-	-	-
senilis I (61-70 years)	-	-	-	-	-	-	-	-
senilis II (71 and more)	-	-	-	-	-	-	-	-
unknown age	-	-	-	-	-	-	-	-
TOTAL NUMBER OF INDIVIDUALS	3		-		-		3	

Table 10. Sex and age structure of individuals

Табела 10. Полна и старосна структура индивида

Note: The grave construction was destroyed by grave robbers. It is situated above the Late Roman grave 123.

ANTHROPOLOGICAL ANALYSIS:

In the grave, skeletal remains of an adult male individual, aged 46, were discovered.⁷⁸

The perceived paleopathological changes are traces of several injuries on the frontal bone (Pl. XI, 3) and several fused fractures on the postcranial part of the skeleton (these are fused fractures of the ribs (Pl. XI, 4), the right ulna and the *malleolus lateralis* of the right fibula). The injuries on the frontal bone, in the form of shallow perforated circular depressions, are present in two almost parallel lines (Pl. XI, 3).⁷⁹ Although serious, these injuries on the frontal bone, most probably inflicted by a blunt object, which had on it several spikes (*cestus?*), show traces of healing. Other noticeable paleopathological changes are osteoarthritis (on the left glenoid cavity, on the 1st metacarpal bone, on the pubic and ischiadicus parts of both pelvic bones, on both patellas, and on the ends of the femurs and tibias), Schmorl's nodes (on five thoracic and one lumbar vertebrae), osteoporosis (on vertebrae L1–L5) and *osteochondritis dissecans* (on both *os capitata*).

Dental analysis indicated the presence of the following teeth in the jaws: 13 (root), 14 (root), 22 (root), 23 (root), 25 (root), 28, 31 (root), 33, 34, 42, 43 and 44. Teeth 15, 21 (?), 24, 26, 27 (one root), 45 and 46 were lost ante-mortem, and teeth 11, 12, 32, 35 and 41, post-mortem. Abrasion of the 1st degree (in enamel) was noted on tooth 28, of the 2nd degree (exposed dentin)

on tooth 34, of the 3rd degree (to the bottom of the fissure) on teeth 33 (→ 4th) and 43 (→ 4th), and of the 4th degree (pulp exposure) on teeth 13, 14, 22, 23, 25, 31, 42 and 44. Parodontopathy is very pronounced on the maxilla and mandible. Caries was noted on tooth 28 (mesial, between the crown and the root, 0.3 cm in diameter). A periapical cystic cavity, as a result of caries, is visible labially on tooth 22 (0.5 cm in diameter) and buccally on tooth 27 (0.7 cm in diameter). Occlusion: tête-à-tête.

The epigenetic characteristics noticeable on the *norma frontalis* are openings and notches in the supra-orbital region, on the *norma verticalis* – *foramina parietalia* (one on the right and one on the left), on the *norma occipitalis* – *linea nuchae suprema* (very pronounced), on the *norma lateralis* – two *foramen zygomaticofaciale* (on the left zygomatic bone) and *sutura squamomastoidea* (on both mastoid processes). On the postcranial part of the skeleton, *perforatio fossae olecrani* on the left humerus was also noted.

Markers of occupational stress in the form of hypertrophy (cortical defect) are visible on the muscle attachment points of the ribs (*Mm. levatores costarum*), left scapula (*m. triceps brachii* – *Caput longum, m.*

⁷⁸ Degree of bone preservation: category III (moderately preserved cranial and postcranial skeleton).

⁷⁹ The frontal bone around the first two depressions was damaged post-mortem.

stature (cm)	GRAVE 100	GRAVE 102	GRAVE 108
humerus	-	-	171 ± 5
radius	-	-	170 ± 5
ulna	-	183 ± 5	173 ± 5
femur	-	172 ± 4	170 ± 4
tibia	171 ± 4	176 ± 4	-
fibula	-	-	-
medium	171 ± 4	177 ± 4	171 ± 5

Table 11. Stature

Табела 11. Телесна висина

subscapularis, *m. infraspinatus*, *m. teres minor*, *m. teres major*, left humerus (*m. brachioradialis*, *m. brachialis*, *m. extensor carpi radialis longus*, *m. extensor carpi radialis brevis*, *m. extensor digitorum*, *m. extensor digiti minimi*, *m. extensor carpi ulnaris*, *m. supinator*; *m. pronator teres*, *m. flexor carpi radialis*, *m. palmaris longus*, *m. flexor carpi ulnaris*, *m. flexor digitorum superficialis*, *m. triceps brachii – Caput mediale*, *m. flexor carpi ulnaris*, *m. anconeus*), right and left ulna (*m. flexor digitorum superficialis*, *m. pronator teres*, *m. brachialis*, *m. supinator*, *m. flexor digitorum profundus*, *m. pronator quadratus*, *m. triceps brachii*, *m. anconeus*, *m. flexor digitorum profundus*, *m. flexor carpi ulnaris*, *m. extensor carpi ulnaris*, *m. abductor pollicis longus*, *m. extensor pollicis brevis*, *m. extensor pollicis longus*, *m. extensor indicis*) (Pl. XI, 5), right radius (*m. brachioradialis*, *m. pronator quadratus*, *m. extensor digitorum*, *m. extensor indicis*, *m. extensor pollicis longus*, *m. extensor carpi radialis brevis*, *m. extensor carpi radialis longus*, *m. abductor pollicis longus*, *m. extensor pollicis brevis*), left radius (*m. pronator teres*, *m. abductor pollicis longus*, *m. extensor pollicis brevis*, *m. supinator*, *m. biceps brachii*, *m. flexor digitorum superficialis*), right femur (*m. iliopsoas*, *m. adductus magnus*, *m. gluteus maximus* (and all others along the *lineae asperae*), *m. gastrocnemius – Caput mediale*, *m. adductor magnus*, *m. plantaris*, *m. gastrocnemius – Caput laterale*, *m. popliteus*) (Pl. XI, 6–7) and left femur (*m. piriformis*, *m. gluteus minimus*, *m. vastus lateralis*, *m. iliopsoas*, *m. adductus magnus*, *m. quadriceps femoris*, *m. gluteus maximus* (and all others along the *lineae asperae*), *m. gastrocnemius – Caput mediale*, *m. adductor magnus*, *m. plantaris*, *m. gastrocnemius – Caput laterale*, *m. popliteus*). Markers of occupational stress in the form of hypertrophy (cortical

CRANIAL SKELETON	GRAVE 100	GRAVE 108
Primary cranial measures		
Cranial Index	-	80.59 brachycranial
Cranial Length-Height Index	-	72.35 orthocranial
Cranial Breadth-Height Index	-	89.78 tapeinocranial
Mean Height Index	-	80.13 medium
Approximate Cranial Size	-	14.33
Mean Porion-Height Index	-	72.96 high
Index of Flatness of the Cranial Base	-	5.69 low
Fronto-Parietal Index	-	69.34 metriometopic
Prognathic Index	-	91.21 ortognathic
Facial Skeleton		
Total Facial Index	-	92.91 leptoprosopic
Upper Facial Index	-	55.90 leptenic
The Nose		
Nasal Index	-	43.14 leptorrhinal
The Orbits		
Orbital Index	-	86.84 mesoconchic 89.74 mesoconchic
Maxilla		
Maxilloalveolar Index	-	121.43 brachyuranial
The Palate		
Palatal Index	-	75.55 leptostaphylnic
Mandible		
Mandibular Robustness Index	35	40.32
Mandibular Branch Index	44.93	42.74
Fronto-mandibular Index	-	97.43 mesomandibular

Table 12. Indices on the cranial skeleton

Табела 12. Индекси на кранијалном скелету

POSTCRANIAL SKELETON	GRAVE 100	GRAVE 102	GRAVE 108
Humerus			
Robusticity Index	-	-	17.19
	-	-	17.98
Cross-Section Index	83.33	-	85
	86.96	78.18	87.18
Radiohumeral Index	-	-	-
	-	-	75.71
Radius			
The Length-Thickness Index	-	-	-
	-	-	16.89
Cross-Section Index	-	-	-
	-	-	4.89
The Length-Breadth Index	-	-	-
	-	-	14.44
Ulna			
Caliber Index	15.22	18	17.57
	-	-	-
Femur			
Robusticity Index	-	14.50	11.36
	-	15.22	11.67
Pilastric Index	-	127.59	104.08
	-	108.57	104
Platymeric Index	-	69.23 platymeric	73.01 platymeric
	-	68.83 platymeric	85.18 eurymeric
Tibia			
The Length-Breadth Index	18.48	-	-
	-	21.28	-
Platycnemic Index	76.12 eurycnemic	-	79.66 eurycnemic
	67.65 mesocnemic	73.96 eurycnemic	85.45 eurycnemic
Fibula			
The Length-Breadth Index	11.85	-	-
	-	-	-

Table 13. Indices on the postcranial skeleton

Табела 13. Индекси на постранијалном скелету

defect) are also visible on the ligament attachment points of both femurs (*lig. iliofemorale*, *lig. pubofemorale*, *lig. cruciatum posterius*, *lig. cruciatum anterius*). The olecranons of both ulnas are slightly separated.

Other observations: Brown traces made by metal oxidation are visible on the ribs, left scapula, lower end of the left humerus, lower end of the left tibia, ends of the left femur and on the right pelvic wing. The position of the stains made by metal (iron) oxidation indicates that the deceased might have been buried with weapons (these are most likely a spearhead at shoulder height, a long sword along the left arm and left leg, and a short dagger in the region of the right pelvic bone).

Grave 108

Sondage F I (VII)/1995.

Rectangular grave construction, a cist of tegulae laid edgewise, dimensions: 1.80 x 0.50 m. Bottom tiled with horizontally laid bricks, at a relative depth of 2.00 m.

Orientation: west-east.

Skeleton dislocated.

No finds.

Note: The upper part of the grave construction, the lid of the cist, which most likely consisted of horizon-

tally laid tegulae, was destroyed by grave robbers. The grave is situated above the Late Roman grave 128.

ANTHROPOLOGICAL ANALYSIS:

In the grave, skeletal remains of a juvenile male individual, aged about 20, were discovered.⁸⁰

The perceived paleopathological changes are traces of several injuries. Most obvious of these is a tri-bladed arrow inflicted injury (right *facies orbitalis*) (0.7 x 0.7 x 0.7 cm in size) with traces of healing (Pl. XII, 1–3).⁸¹ Unfortunately, the eye could not have been saved. Injuries also worth mentioning are those in the form of shallow depressions on the right *processus zygomaticus* and on the mandible (left of the mentum) (Pl. XII, 2–3). Other noticeable paleopathological changes are anomalies in the skeletal development (*foramen sternale*, a cleft below the dens on the body of the axis), osteoarthritis (on the olecranon of both ulnas and on the heel bones), Schmorl's nodes (on T6–T12 and on L1 and L2 (Pl. XII, 5), 1–2.5 cm in length and 0.5–1 cm in width), dislocation of the right foot,⁸² a slight collapse of the body of the thoracic and lumbar vertebrae, *cribra orbitalia* (particularly on the roof of the left orbit), *cribra humera* (near the upper ends of both humeri; the surface area of the affected parts of the bones is 1.5 x 1.5 cm and 1.2 x 1 cm), *cribra femora* (near the upper ends of both femurs; the surface area of the affected parts of the bones is 2.5 x 1.5 cm and 1.5 x 3 cm), osteoporosis (on vertebra L5), infectious osteomyelitis (on the right talus and the right calcaneus) and *osteochondritis dissecans* (on the right and left 3rd metatarsal bone, 1 x 1 cm in size).

Dental analysis indicated the presence of the following teeth in the jaws: 13, 15, 16, 17, 22, 23, 24, 25, 26, 27, 32, 33, 36, 37, 38, 42, 43, 44, 45, 46, 47 and 48. Teeth 11, 12, 14, 21, 28, 31, 34, 35 and 41 were lost post-mortem. Abrasion of the 1st degree (in enamel) was noted on teeth 15, 17, 22, 23, 32, 33, 37, 38, 43, 44, 45, 47 and 48, of the 2nd degree (exposed dentin) on teeth 16, 42 and 46, and of the 3rd degree (to the bottom of the fissure) on teeth 26 and 36. Hypoplasia, calculus and parodontopathy (moderately pronounced on the maxilla) were mildly pronounced. Decolourisation of the enamel is visible on the labial and buccal side on the maxillary teeth. The present jaw and dental arch anomalies are hypodontia of tooth 18, the distal rotation of tooth 32 (30°), the labial curvature of tooth 24 and lingual of teeth 37, 38, 44 and 48. Caries was noted on tooth 17 (occlusal, in the form of a dot) and 27 (occlusal, in the form of a dot). Occlusion: tête-à-tête.

The noticeable epigenetic characteristic on the *norma occipitalis* is *os sutura lambdoidea* (one on the right side, 1.1 x 0.5 cm in size). On the postcranial part of the skeleton, *foramen processus transversi bipartitum* on C5 was also observed.

Markers of occupational stress in the form of the hypertrophy (cortical defect) are visible on the muscle attachment points of the right and left clavicle (*m. deltoideus*), right and left scapula (*m. triceps brachii – Caput longum*), right and left humerus (*m. deltoideus*, *m. brachialis*), right and left ulna (*m. brachialis*) (Pl. XII, 4), both femurs (*m. adductor magnus*). The clavicles are slightly deformed in the direction from superior to inferior (it is possible that this, as well as the occurrence of Schmorl's nodes, is a consequence of carrying heavy loads).⁸³ The olecranon of both ulnas are slightly separated. Additional facets are visible on the lower ends of the right and left 1st metatarsal bone.

DISCUSSION

Burying the deceased with belt sets and fibulae, which are not only items of clothing but also military equipment, is a common occurrence in Roman necropolises throughout the Empire. Military belts and certain types of fibulae were an indication of military rank and/or a specific unit, and at the same time they revealed the social status of the person who wore them.⁸⁴ Therefore, it was preferable for the deceased to be buried in a “uniform”, with items of military equipment which defined him as a member of the military elite. This was of particular importance in the border provin-

⁸⁰ Degree of bone preservation: category II (incomplete, well preserved cranial and postcranial skeleton).

⁸¹ The entry angle of the arrow undoubtedly shows that, when wounded, this youth was probably on a higher elevation in relation to the opponent, or maybe on a horse. (Pl. XII, 1–3).

⁸² There are almost no individuals in these 17 graves who did not have some kind of problem with ankle joints (osteoarthritis, sprains or dislocations). Ankle joints in wartime circumstances obviously suffered a great deal of pressure. What contributed to it most was the carrying/wearing of heavy military equipment, pivoting and swift changes of direction in battle, jumping over obstacles, jumping from heights, dismounting from a horse, etc.

⁸³ The military equipment of Roman soldiers was extremely heavy. Just the wooden containers with leather straps, similar to modern backpacks, weighed 20–40 kg.

⁸⁴ Bullinger 1969, 68–70; Petković 2011a, 121–124; Quast 2012, 254–256.

ces. On the other hand, the graves in which weapons were placed along with the deceased are rare in the necropolises of the Roman period but they do, however, appear in all provinces of the Empire.⁸⁵ The genesis and significance of these graves differ from one region of the Roman Empire to the next. In the region of the central Balkans, three typologically and chronologically differentiated groups of Roman graves with weapons are found:

1. graves with cremated deceased, of the Mala Kopašnica – Sase type, dated to the 2nd and the first half of the 3rd century, in which the inclusion of weapons and military equipment can be explained by a strong autochthonous tradition and weak Romanisation,⁸⁶

2. graves with cremated and inhumed deceased – masonry tombs, tumuli and sarcophagi of members of the provincial military elite, dated to the last decades of the 3rd and the beginning of the 4th century, the Tetrarchy period, whereby weapons and military equipment are included as insignia of the status of the buried individual, as a consequence of the merging of autochthonous tradition and Roman culture,⁸⁷

3. graves with inhumed deceased, in freely dug pits or in cists made of tegulae, dated to the second half of the 4th and the first half of the 5th century, in which burial with weapons is a consequence of the acceptance of “barbarian” funereal customs into the Late Roman culture.⁸⁸

What have not been considered here are graves with weapons which can undoubtedly be ascribed to barbarian populations in the territory of the Empire, such as the eastern Germanic *foederati*, noted in separate necropolises of the 5th century at Singidunum and Viminacium.⁸⁹

The burial with weapons in grave 97 belongs to phase II of the Slog necropolis, that is to the period after the Battle of Hadrianopolis, in the last decades of the 4th and first decade of the 5th century, when the fortification’s garrison consisted of an equestrian unit of *pseudocomitatenses Timacenses*, an auxiliary unit of light cavalry of the “Alanic type” (Pl. V, G. 97, Pl. VII, 5).⁹⁰ Devastated grave 27 also belongs to the same phase of the necropolis, in which dislocated bones of an adult male individual and a child of about 10 years of age were discovered, along with parts of a bronze belt set and the conical shank of a leaf-shaped arrowhead (Pl. V, G. 27, Pl. VI, 3, Pl. VII, 3). The influence of barbarians recruited to the aforementioned cavalry unit is not only reflected in the material culture of this period of the fortification but also in the grave finds, such as

iron belt buckles with a frame in the shape of the Latin letter B and a prong that exceeds the frame (Pl. VI, 1, Pl. VII, 1, 4), a bronze belt buckle of the “Crimean type”, with a rectangular plate, circular frame and a prong with a zoomorphic thickening on the tip, which exceeds the frame (Pl. VI, 3, Pl. VII, 3) and a fluted glass goblet of a conical shape (Pl. VI, 4), characteristic of the late phase of the Chernyakhov – Sântana de Mureş culture.⁹¹

Furthermore, in grave 97, in the region of the chest of the buried individual, an animal bone, part of the pelvis of a goat or a sheep, was found. This was a remnant of a posthumous feast, given as an offering to the deceased. The placement of meat into the grave is not a part of the Roman burial ritual, whilst posthumous feasts are characteristic of the funerary cult of the late phase of the Chernyakhov – Sântana de Mureş culture.⁹² It is therefore fair to assume that the buried men were newcomers, most probably recruited from within the ranks of the Danube *foederati*. In addition, the type of the weaponry points to the Gothic *foederati* from the Lower Danube, the majority of which made up the

⁸⁵ Diaconescu 1999, 204–206, 215–216; Quast 2012, 247–256, Fig. 8; Tejral 2012, 118–120, Fig. 3.

⁸⁶ Such graves were noted at the eponymous necropolis of the cremated deceased near Leskovac, at the Više Grobalja necropolis at Viminacium and at the necropolis in Davidovac, near Vranje. (Зотовић 1968, 24; Фидановски, Цвијетићанин 2005, 91, 93, Т. III, 2, Т. IV, 5, graves XIV and XVII; Зотовић, Јордовић 1990, 84, 93, 103, Т. LXXXV, 7, Т. CXXXII, 4, Т. CLXXIV, 4, G1–58, G1–137, G1–222).

⁸⁷ Burials of this group were noted in Silistra (*Durostorum*) in Bulgaria, Taranes in Macedonia, at Gamzigrad (*Romuliana*) and Šarkamen in Serbia, and Hârşova (*Carsium*) in Romania (Diaconescu 1999, 205–206, Abb. 2–3; Ivanovski 1987; Petković 2009, 253 *et sequ.*, Figs. 4–12; Tomović *et al.* 2005, 44–45, 170–172, G. 6, Cat. 90).

⁸⁸ We assume that there is a larger number of burials of this type at Roman necropolises in Serbia although, apart from G. 27 and G. 97 from the site of Slog in Ravna (*Timacum Minus*), we are only familiar with one grave from Čuprija (*Horreum Margi*) and one from the necropolis at Viminacium – Više Grobalja (Piletić 1969, 21–22, sl. 28, sl. 38; Korać, Golubović 2009, 365, G–443).

⁸⁹ Ivanišević, Kazanski 2009, 126–129.

⁹⁰ Petrović 1995, 34; Petković 1999, 225–228.

⁹¹ Tejral 1999, 242–248, Abb. 18, 21–22; Kazanski 2012, 383–386, Fig. 2 – graves which contain similar finds, a belt buckle and a conical glass goblet, as well as weapons, most commonly leaf-shaped spearheads, long swords, faceted conical shield umbos, and occasionally horse tack, appear in the last third of the 4th and at the beginning of the 5th century north-east of the Danube Limes, as well as in the Lower Danube and on the northern coast of the Black Sea.

⁹² Magomedov 2000, 59–63.

infantry, but also the equestrian units formed under the influence of Sarmatian tribes, primarily the Alans.⁹³ In any case, the Alano-Hunnic steppe component of the auxiliary units of the Roman light cavalry, in the eastern part of the Empire in the time of Theodosius I, can also be observed at the Late Roman Slog necropolis through the finds of the tri-bladed arrowheads (Pl. VI, 5).⁹⁴ Along with the numerous recorded injuries (cuts on the head and the fused fissure of the right tibia (grave 15), injuries to the *processus zygomaticus* (grave 26) and injuries to the head in the region of the asterion (grave 123)), what is surely worth mentioning are the cases of scurvy observed in the individuals buried in graves 28 and 76, which would indicate that they moved over to the Timok valley, or that they resided over a longer period of time outside of this fertile area, which could provide fruit and vegetables rich in vitamins.

Although the grave finds from phase I of the Slog necropolis do not essentially differ from those from graves of the subsequent phase (Pl. II–III), the component of the regular Roman army is more prominent, which is reflected in the finds of crossbow fibulae (Pl. II, 1, 6) and bronze belt sets (Pl. III, 1–2). Generally, it is possible that they are members of the same military unit, *pseudocomitatenses Timacenses auxiliarii*, or officers of the *II Aurelia Dardanorum* equestrian cohort, which unquestionably made up the *Timacum Minus* garrison from the middle of the 2nd to the end of the 3rd or the beginning of the 4th century, possibly even to the last quarter of the 4th century, that is to the Battle of Hadrianopolis in 378.⁹⁵ However, what should not be ruled out are the equestrian units of *Numeri Dalmatorum*, testified to by stamps on bricks from the 4th phase of the fortification reconstruction, during the period of the reign of Valentinian I and Valens (364–375).⁹⁶ That they were really warriors is also confirmed by, among other things, a cut inflicted by a sharp blade, most likely a sword or knife, on the mentum and a fissure of the right tibia (grave 91), an injury on the right femur (grave 99) and a *myositis ossificans traumatica* noted on the left tibia (grave 141).

In phase III of the Slog necropolis, three graves were noted, in which adult male individuals were buried who, in the course of their lifetime, acquired injuries in battle and/or characteristic pathological changes on the bones caused by military life, fractures of the right fibula, the neck of the right femur and the ribs, and a subperiosteal hematoma on the right tibia (grave 100), injuries on the frontal bone, in the form of shallow perforated circular depressions present in two

almost parallel lines, and fractures of the ribs, right ulna and right fibula (grave 102)⁹⁷ and a transfixing injury caused by a tri-bladed arrow, and injuries to the *processus zygomaticus* and mentum (grave 108). These graves are without finds, except for the iron belt buckle with a circular frame from grave 102 (Pl. VII, 6). However, what should be taken into account is that all three graves were destroyed by grave robbers, the skeletons were dislocated, and that the most valuable parts of the military equipment, such as the fibulae and the belt sets were probably stolen from the pits. On the other hand, in most graves of adults and children of both sexes in this phase, there were no finds, indicating two facts – the population of *Timacum Minus* were Christian and they were poor. What bears testament to this fact are the cultural layers in the fortification from the period of the first half of the 5th century, during which time an almost rural settlement emerged within its walls, comprising structures of light materials and crudely and poorly adapted older buildings.⁹⁸

The deceased buried in grave 108 might also have belonged to the non-Roman population, considering that, at the approximate age of 20 he had already been seriously wounded and had ailments caused by military life. Generally speaking, Roman citizens did not join the army before they turned 17 or 18 years of age, although for the recruited “barbarians” this rule did not apply. Thus, this young warrior most probably started service at the age of 14 or 15, resulting in pathological changes on the spine. The impression given is that *Timacum Minus* once again experienced changes to its population at the beginning of the 5th century, considering the graves from phase III, containing no offerings, and with a west-east orientation almost without exception, which testifies to complete Christianisation.

⁹³ Kazanski 2013, 494–502, 504–506.

⁹⁴ Kazanski 2013, 513.

⁹⁵ Petković *et al.* 2005, 13, Note 3.

⁹⁶ Petrović 1995, 34 – stamps NVMDIIII and NVMDIIII were noted on the bricks.

⁹⁷ This specific individual, in addition to a large number of injuries along with evidence of an athletic built on the skeleton, displayed the highest levels of occupational stress in the entire Slog necropolis, thus his “barbarian” origins can be assumed.

⁹⁸ Петковић, Јовановић 2000, 279–280; Petković, Ilijić 2013, 53–54, 65–68 – this horizon of life at *Timacum Minus* was explored in the sector of the southern gate of the fortification and in the large building in its interior, considered by previous researchers to be a *horreum*.




Fig. 2. Medical instruments discovered at the archaeological site *Timacum Minus*, now in the archaeological exhibition of the Homeland Museum of *Knjaževac*

Сл. 2. Медицински инструменти откривени на археолошкоком налазишту *Timacum Minus*, сада у археолошкој поставци Завичајног музеја у *Књажевицу*

CONCLUSION

Based on the analysis of the military graves from the Slog necropolis, several conclusions regarding the population of the Late Roman settlement and fortification *Timacum Minus* can be drawn.⁹⁹ The population was composed of Romanised natives, with a prominent autochthonous Dardanian-Tribalian component (*Timachi*) and newcomers, who settled in several waves from the last quarter of the 3rd to the first half of the 5th century.¹⁰⁰ The newcomers always came from the left bank of the Danube, either from the abandoned Romanised Dacia or from the territory in Thrace where the *foederati* originated, which is testified to by pronounced material elements of the Chernyakhov – Sântana de Mureș culture. This population was integrated, as demonstrated by the distribution of the graves in all three phases of the Late Roman Slog necropolis (Plan 2). The graves were, most likely, grouped according to family ties rather than ethnic background or social status. This conclusion is based on the fact that the elements of a “barbarian” material culture appear

sporadically, so one can speak of the barbarisation of the *Timacum Minus* population rather than of the stationing of military units comprising the barbarians, the Goths, the Alans or the Huns. On the other hand, the socio-economic standing of the population buried at the Slog necropolis is very uniform and could be described as very modest. However, the individuals buried in the analysed military graves generally lived well into adulthood, despite frequent wounding and very serious injuries, as well as evidence of a gruelling military life. It is not possible to determine whether these are retired soldiers, veterans, or active warriors but, based on the individual of approximately 20 years of age buried in

⁹⁹ A small scale archaeological exploration of the civil settlement revealed horizons of life from the 2nd to the end of the 4th century, which leads to the conclusion that it was moved, at the end of the 4th and the beginning of the 5th century, most likely to the interior of the fortification (Петровић, Јовановић 1997, 21–24; Петковић, Илијић 2012).

¹⁰⁰ Petković, Ilijić 2013, 63–65.

grave 108, who already had traces of serious injuries and pathological changes caused by the carrying of heavy loads and excessive walking, it is evident that they entered into military service at a very early age.¹⁰¹ In the 2nd–3rd century, *Timacum Minus* was an attractive place for veterans to settle due to the natural resources in the area, the fertile soil and mining potential, testified to by the epigraphs on gravestones and votive monuments.¹⁰²

The warriors buried in the Late Roman Slog necropolis belonged to an equestrian unit, which is confirmed by the characteristic stress markers on the osteological material, particularly in the cases of the deceased buried in graves 15, 76, 91, 100, 102, 108, 123 and 141. Most likely these were light cavalry archers (graves 15, 25, 76, 91, 99, 100, 102, 108, 123 and 141) who could engage similar barbarian units. This is evident in both the injuries of the individuals from graves 15, 26, 76, 91, 99, 100, 102, 108 and 123, and the weapons placed in graves 27, 97 and 102. In the case of the deceased from graves 27 and 97, these are tri-bladed and leaf-shaped arrowheads (Pl. VI, 5, Pl. VII, 3, 5–6). Regardless of the relative poverty of the population of the Late

Roman *Timacum Minus*, the military population buried at the Slog necropolis had, despite all the hardships of military life, very good and efficient medical care, given that the majority of the serious injuries were treated in such a way that they left no major consequences on the individual's health and life (Pl. IV, 1, Pl. VIII, 1–3, Pl. XI, 1–3, Pl. XII, 1–3). This indicates that the *Timacum Minus* fortification had one or more military surgeons. A medical service in this fortification in the previous period is evidenced by the gravestone of the medicus of the II Aurelius cohort of Dardanians, *Titus Aelius Martialis*,¹⁰³ as well as a votive monument devoted to Aesculapius, a patron of doctors and healers, and several surgical instruments found in Ravna (Fig. 2).¹⁰⁴

The analysis of the military graves from the Slog necropolis confirmed the results of the previous research of the Late Roman period in eastern Serbia, in the Roman province of *Dacia Ripensis*, as well as the hypothesis about the garrisons of light cavalry in the fortifications of the Timok region. Characteristics of the Late Roman material culture of this region are militarisation, barbarisation, Christianisation and ruralisation, which announce the onset of the Early Medieval period.¹⁰⁵

¹⁰¹ Similar changes on bones caused by the carrying of heavy loads were noted in the individual from grave 15.

¹⁰² Petković, Ilijić 2013, 63, Table 1.

¹⁰³ Petrović 1995, 97, No. 49 – *D(is) M(anibus) | T. Ae(lio) | Mar[ti]a[l(i)] med(ico) | co[h(ortis)] II Aur(eliae) | Dar(danorum)...*

¹⁰⁴ Petrović 1995, 63, No. 1; Јовановић 1989, 92–93.

¹⁰⁵ Petković *et al.* 2005, 143–145; Petković 2011 b, 122–126.

BIBLIOGRAPHY:

Bass 1995 – W. M. Bass, *Human Osteology, A Laboratory and Field Manual*. Columbia: Missouri Archaeological Society 1995.

Brothwell 1981– D. R. Brothwell, *Digging up bones*. London: British Museum (Natural History) and Oxford: Oxford University Press 1981.

Buikstra and Ubelaker 1994 – J. E., Buikstra and D. H., Ubelaker, *Standards for data collection from human skeletal remains*. Arkansas Archeological Survey Research Series, No 44. Fayetteville, Arkansas: Arkansas Archeological Survey 1994.

Bullinger 1969 – H. Bullinger, Spätantike Gürtelbeschläge, Brügge: Dissertationes Archaeologiae Gadenses 12, 1969.

Цвијетићанин 2006 – Т. Цвијетићанин, *Касноантичка глеђосана керамика. Глеђосана керамика Прве Мезије, Приобалне Дакије, Средоземне Дакије и Дарданије*, Београд: Народни музеј 2006.

Diaconescu 1999 – A. Diaconescu, *Ornamenta dignities*. Gradabzeichnung Symbole des Sozialen Status bei idem Lokalen Eliten von Dakien nach dem Aurelianischen Rückzug, *Acta musei Napocensis* 36, 1, 1999, 203–241.

Душанић 1980 – С. Душанић, Организација римског рударства у Норик, Панонији, Далмацији и Горњој Мезији, *Историјски Гласник* 1–2, 1980, 7–55.

Dušanić 1996 – S. Dušanić, Late Roman Mining in Illyricum: Historical Observations, in: *Ancient Mining and Metallurgy in Southeast Europe, International Symposium, Donji Milanovac, May 20–25, 1990*, ed: P. Petrović, S. Đurđekanić, B. Jovanović, Belgrade, Bor: Archaeological Institute, Museum of Mining and Metallurgy 1996, 219 – 225.

Ђурић-Срејић 1995 – М. Ђурић-Срејић, *Увод у физичку антропологију древних популација*. Београд: Завод за уџбенике и наставна средства 1995.

Ferembach, Schwidetzky and Stloukal 1980 – D. Ferembach, I. Schwidetzky and M. Stloukal, Recommendations for age and sex diagnosis of skeletons. *Journal of Human Evolution* 7, 1980, 517–549.

Фидановски, Цвијетићанин 2005 – С. Фидановски и Т. Цвијетићанин, Римска вила и некропола на локалитету Каменица – Моравиште у Малој Копашници код Грделице (Roman Villa and Necropolis at the Site Kamenitica–Moravište in Mala Kopašnica near Grdelica), у: *E 75, Археолошка истраживања, свеска 1/2004 (Archaeological Research, Volume 1/2004)*, ур: М. Vrbolić, Београд 2005, 50–121.

Garn, Lewis and Kerewsky 1965 – S. Garn, A. Lewis and R. Kerewsky, X – linked inheritance of teeth size. *Journal of Dental Research* 44, 1965 439–441.

Hauser and De Stefano 1989 – G. Hauser and G. F. De Stefano, *Epigenetic Variants of Human Skull*. Stuttgart: E. Schweizerbart'sche Verlagsbuchhandlung 1989.

Hillson 1990 – S. Hillson, *Teeth*. Cambridge: Cambridge University Press 1990.

Hillson 1996– S. Hillson, *Dental Anthropology*. Cambridge: Cambridge University Press 1996.

Ијић 2009 – В. Ијић, *Римско утврђење Timacum Minus*, Књажевац: Завичајни музеј Књажевац 2009.

Илијић 2011 – Б. Илијић, Примена геофизичких метода на археолошком налазишту *Timacum Minus*, *Развитак, година L, број 239–240/2011, 50 година*, 2011, 78–86.

Işcan, Loth and Wright 1984a – M. Y. Işcan, S. R. Loth and R. K. Wright, Metamorphosis at the sternal rib end: A new method to estimate age at death in males. *American Journal of Physical Anthropology* 65, 1984, 147–156.

Işcan, Loth and Wright 1984b – M. Y. Işcan, S. R. Loth and R. K. Wright, Age estimation from the rib by phase analysis: White males. *Journal of Forensic Sciences* 29, 1984, 1094–1104.

Işcan, Loth and Wright 1985 – M. Y. Işcan, S. R. Loth and R. K. Wright, Age estimation from the rib by phase analysis: White females. *Journal of Forensic Sciences* 30, 1985, 853–863.

Ivanišević, Kazanski 2009 – V. Ivanišević, M. Kazanski, Nouvelle nécropole des Grandes migrations de Singidunum, *Starinar LVII/2007* (2009), 115–137.

Ivanovski 1987 – M. Ivanovski, The Grave of a Warrior from the Period of Licinius I found at Taraneš, *Archaeologia Jugoslavica* 24, 1987, 81–90.

Jeremić 2009– G. Jeremić, *Saldum. Roman and Early Byzantine Fortification*, Belgrade: Archaeological Institute 2009.

Јовановић 1989 – С. Јовановић, Римски медицински споменици из тврђаве Timacum Minus код села Равне, *Развитак, год. XXIX, бр. 1*, 1989 (Зајечар), 90–93.

Kazanski 2012 – M. Kazanski, Radaigaise et la fin de la civilization Černjahov, in: *The Pontic-Danubian Realm in the Period of the Great Migration*, ed: V. Ivanišević, M. Kazanski, Collège de France – CNRS, Centre de recherché d'histoire et civilization de Byzance, Arheološki institut, Paris–Beograd 2012, 381–403.

Kazanski 2013 – M. Kazanski, in: *War and Warfare in Late Antiquity*, ed: A. Saramtis, N. Christie, Brill–Leiden–Boston 2013, 493–522.

Korać, Golubović 2009 – M. Korać and S. Golubović, *Viminacium 2. Više grobalja*, Beograd: Arheološki institut 2009.

Lovejoy 1985 – C. O. Lovejoy, Dental Wear in the Libben Population: Its Functional Patterns and Role in the Determination of Adult Skeletal Age at Death. *American Journal of Physical Anthropology* 68, 1985, 47–56.

Lovejoy et al. 1985 – C. O. Lovejoy et al., Chronological matamorphosis of the auricular surface of the ilium: A new method for the determination of skeletal age at death. *American Journal of Physical Anthropology* 68, 1985, 15–28.

Magomedov 2000 – B. Magomedov, The tradition of ritual feasts as a part of burial customs in Chernyakhov–Sintana culture, *Archaeologia Bulgarica* IV, 2000 – 2, 59–64.

Mikić 1978 – Ž. Mikić, O antropološkoj metodologiji terenske obrade skeletnih nalaza. *Godišnjak Centra za balkanološka ispitivanja ANUBiH* 16/14: 3–44, 1978, 201–242.

Nagy 2005 – M. Nagy, Zwei Spät Römerzeitlicher Waffengräber am Westenrand der *canabae* von *Aquincum*, *Acta archaeologica ASH* 56 (2005), 403–486.

Petković 1999 – S. Petković, Meaning and Provenance of Horses' Protomes Decoration on the Roman Antler Combs, *Starinar XLIX /1998* (1999), 213–228.

Petković 2009 – S. Petković, Late Roman Necropolis of Romuliana. Area South of the Fortified Palace (Research 2005–2006), *Starinar LVII/2007* (2009), 251–275.

Petković 2010 – S. Petković, *Rimske fibule u Srbiji od I do V veka n.e.*, Beograd: Arheološki institut 2010.

Petković 2011a – S. Petković, The Crossbow Fibulae from Gamzigrad (*Romuliana*), *Starinar LX/2010* (2011), 111–136.

Petković 2011b – S. Petković, Gamzigrad – *Romuliana* in der Zeit nach dem Kaiserlichen Palast, in: *Bruckneudorf und Gamzigrad. Spätantike Pälaste und Großvillen im Donau-Balkan Raum, KVF Band 15*, Hrsg: G. von Bülow, H. Zabelhicky, Römisch-Germanische Kommission des Deutschen Archäologische Instituts, Österreichisches Archäologische Institut, Bonn 2011, 113–128.

Petković et al. 2005 – S. Petković, M. Ružić, S. Jovanović, M. Vuksan, Zs. Zoffmann, *Roman and Medieval Necropolis in Ravna near Knjaževac*, Beograd: Archaeological Institute 2005.

Петковић, Илијић 2012 – С. А. Петковић, Б. Илијић, Прилог проучавању римског насеља на локалитету *Timacum Minus* код Књажевца, *Гласник САД* 28, 2012, 153–178.

Petković, Plijić 2013 – S. Petković, B. Plijić, Votive Altar of *Lucius Petronius Timachus*, *Starinar LXIII/2013*, 53–72.

Петковић, Јовановић 2000 – С. Петковић, С. Јовановић, Археолошка ископавања римског утврђења *Timacum Minus* код села Равна, општина Књажевац током 1997–1998. године – сектор јужне капије, *Старинар L/2000*, 275–280.

Петковић, Радиновић, Илијић 2014 – С. Петковић, Н. Радиновић, Б. Илијић, Археолошка истраживања некрополе Слог у Равни код Књажевца 2013. године, *Развитак, тог. LII, бр. 243–244*, Зајечар 2014, 33–38.

Petrović 1995 – P. Petrović, *Inscriptions de la Mésie Supérieure III – 2. Timacum Minus et la Vallé du Timok*, Beograd: Centre d'étude des épigraphiques et numismatiques de la Faculté de philosophie de l'Université de Beograd 1995.

Petrović 1996 – P. Petrović, Der römische Bergbau in Ravna. Einige Archäologische Notizen, in: *Ancient Mining and Metallurgy in Southeast Europe, International Symposium, Donji Milanovac, May 20–25, 1990*, eds: P. Petrović, S. Đurđekanić, B. Jovanović, Belgrade, Bor: Archaeological Institute, Museum of Mining and Metallurgy, 1996, 195–202.

Петровић, Јовановић 1997 – П. Петровић, С. Јовановић, *Културно блато књажевачког краја. Археолошја*, Београд–Књажевац: Археолошки институт, Завичајни музеј Књажевац.

Piletić 1969 – D. Piletić, Rimaki kastrum Ćuprija – Horreum Margi, *Vesnik Vojnog muzeja* 15 (Beograd), 1997, 9–57.

Quast 2012 – D. Quast, Martial writers – Intellectual warriors: Remarks on a group of Late Antique male graves, in: *The Pontic-Danubian Realm in the Period of the Great Migration*, eds: V. Ivanišević, M. Kazanski, Collège de France – CNRS, Centre de recherche d'histoire et civilization de Byzance, Arheološku institut, Paris–Beograd 2012, 243–262.

RIC VII – P. M. Brunn, *Constantine and Licinius (313–337)*, *Roman Imperial Coinage, Vol. VII*, London 1966: Spink and son, Ltd.

Ružić 1994 – M. Ružić, *Rimsko staklo u Srbiji*, Beograd: Centar za arheološka istraživanja Filozofskog fakulteta 1994.

Scheuer and Black 2000 – L. Scheuer and S. Black, *Developmental Juvenile Osteology*. London: Academic Press 2000.

Sommer 1984 – M. Sommer, *Die Gürtel und Gürtelbeschläge des 4. und 5. Jahrhunderts in Römischen Reich*, Bonner Hefte zur Vorgeschichte 22, Bonn: Institut für Vor- und Frühgeschichte der Rheinischen Friedrich-Wilhelms-Universität 1984.

Tejral 1999 – J. Tejral, Die spätantiken militärischen Eliten beiderseits der norisch-pannonischen Grenze aus der Sicht der Grabfunde, in: *Germanen Beiderseits des spätantiken Limes*, Hrsg: T. Fischer, G. Precht, J. Tejral, Archäologische Institut der Universität zu Köln, Archeologický Ústav AVČ, Köln–Brno 1999, 217–292.

Tejral 2012 – J. Tejral, Cultural or ethnic changes? Continuity and discontinuity on the Middle Danube ca A.D. 500, in: *The Pontic-Danubian Realm in the Period of the Great Migration*, eds: V. Ivanišević, M. Kazanski, Collège de France – CNRS, Centre de recherche d’histoire et civilisation de Byzance, Arheološki institut, Paris–Beograd 2012, 115–188.

Todd 1920 – T. W. Todd, Age changes in the pubic bone: I The male white pubis. *American Journal of Physical Anthropology* 3, 1920, 285–334.

Todd 1921a – T. W. Todd, Age changes in the pubic bone: II The pubis of the male Negro–white hybrid; III The pubis of the white female; IV The pubis of the female Negro–white hybrid. *American Journal of Physical Anthropology* 4, 1921, 1–70.

Todd 1921b – T. W. Todd, Age changes in the pubic bone: VI The interpretation of variations in the symphyseal area. *American Journal of Physical Anthropology* 4, 1921, 407–424.

Tomović et al. 2005 – M. Tomović, I. Popović, B. Borić-Brešković, T. Cvijetićanin, S. Stefanović, A. V. Popović, *Šarkamen (Eastern Serbia): A Tetrarchic Imperial Palace. The Memorial Complex*, Belgrade: Archaeological Institute 2005.

Trotter and Gleser 1952 – M. Trotter and G. C. Gleser, Estimation of stature from long bones of American whites and Negroes, *American Journal of Physical Anthropology* 10, 1952, 463–514.

Vallois 1937 – H. W. Vallois, La Durre de la vie chez l’Homme fossile. *L’Anthropologie* 47, 1937, 499–532.

Зотовић 1968 – Љ. Зотовић, Некрополе спаљених покојника на територији Горње Мезије, *Лесковачки зборник VIII*, 1968, 19–30.

Зотовић, Јордовић 1990 – Љ. Зотовић и Ч. Јордовић, *Viminacium I. Некропола Више тробаља*, Београд 1990.

ILLUSTRATION AUTHORS:

photographs – Dr Sofija Petković,

Dr Nataša Miladinović-Radmilović, Nebojša Borić,

Pero Praštalo MSc, Saša Milutinović-Leteći;

plans and drawings of finds – Dr Aleksandar Kapuran,

map and illustration postproduction – Miro Radmilović

Резиме:СОФИЈА ПЕТКОВИЋ, Археолошки институт, Београд
НАТАША МИЛАДИНОВИЋ-РАДМИЛОВИЋ, Археолошки институт, Београд**ВОЈНИЧКИ ГРОВОВИ СА КАСНОАНТИЧКЕ НЕКРОПОЛЕ
СЛОГ У РАВНИ (*TIMACUM MINUS*)***Кључне речи.* – касна антика, некропола, *Timacum Minus*, римска војска, черњаховска култура, повреде нанете оштрим сечивом, тупим предметима и стрелом.

Римско утврђење и насеље на левој обали Белог Тимока, у атару села Равне, на 10 km северно од Књажевца, идентификовано је систематским археолошким истраживањима као *Timacum Minus* (карта 1). О карактеру овог римског налазишта постоји више хипотеза, али је најверодостојнија претпоставка да се ради о утврђеном административном центру горњомезијске рудне области *Territoria metallorum*, која је заузимала североисточни део провинције Горње Мезије, односно касније провинције Приобалну и Средоземну Дакију (*Dacia Ripensis*, *Dacia Mediterranea*). Утврђење је настало још крајем I века н. е., а напуштено је после хунске инвазије у Подунавље, средином V века (сл. 1).

Око утврђеног административног, рударско-металуршког и занатског седишта временом се формирало урбано насеље са јавним купатилима, градским вилама, радионицама и храмовима. Неки од тих објеката су констатовани археолошким ископавањима, док се о другима зна посредно преко откривених скулптура и епиграфских споменика. На основу ових потоњих, узиданих у бедеме и грађевине током реконструкција у касноантичком периоду, од средине III до прве половине V века, утврђено је и постојање велике некрополе у II и III веку. Нажалост, из поменутог разлога, већина надгробних споменика је дислоцирана, тако да се о овој некрополи мало зна. Новија недеструктивна археолошка истраживања, која су користила методе геофизичких мерења, уз податке прикупљене од мештана који обрађују њиве и баште западно од римског утврђења, лоцирају некрополу кремираних покојника из II–III века на потесу Ширина, који се налази између утврђења на истоку, Ропинског потока на северу, брда Слог на западу и Селишког (Зубановог) потока на југу (план 1). С друге стране, делови касноантичке некрополе истражени су на десној обали Ропинског потока, северо-западно од утврђења и на источној падини брда Слог.

Током три кампање заштитних археолошких ископавања, уследњених реконструкцијом локалног пута Равна–Дебелица током 1994–1996. године, са леве стране пута, на источној падини брда Слог истражен је део вишеслојне касноантичке и раносредњовековне некрополе. Откривено је 140 гробова, од чега 72 са 75 сахрањених индивидуа из касноантичког периода (план 2). Констатовано је да се ради о некрополи формираној у три сукцесивне фазе у периоду од средине IV до средине V века: I фаза – од 350. до 380. године, II фаза – од 380. до 410. године и III фаза – од 410. до 450. године. Резултати заштитних археолошких ископавања некрополе Слог публиковани су 2005. године у посебној монографији.¹ Том приликом објављени су и резултати антрополошке анализе, коју је извршила др Жужана Цофман,

антрополог Националног музеја у Будимпешти. Међутим, од 2011. године је у току пројекат обраде, анализе и публикација свих археолошких података и налаза прикупљених током систематских и заштитних археолошких истраживања налазишта Равна – *Timacum Minus*. Нови подаци, добијени ревизијом антрополошког остеоолошког материјала и анализама спроведеним савременим методолошким поступцима, навели су нас да поново размотримо премисе и закључке који се односе на популацију касноантичке Равне. У овом раду смо допунили податке о војничкој компоненти становништва Тимакум Минуса, која је, без сумње, играла значајну улогу у социоекономској слици овога насеља.

Међу истраженим касноантичким гробовима са некрополе Слог у Равни издвојили смо сахране које су садржале археолошке налазе војне опреме и оружје (план 2, Т. I–III, Т. V–VII, Т. X). Детаљном антрополошким анализом остеоолошких налаза из ових гробова преваходно смо покушали да установимо, колико је то степен очуваности костију дозвољавао, присуство антеморталних и периморталних повреда које су настале не као последица несрећних случајева, већ као последица намерног насиља, затим карактеристичних маркера окупационог стреса, и патолошких промена, који би указивали да су покојници били у активној војној служби (Т. IV, Т. VIII–IX, Т. XI–XII).

На основу анализе војничких гробова са некрополе Слог можемо изнети неколико закључака о популацији касноантичког насеља и утврђења *Timacum Minus*. Становништво је било састављено од романизованих староседелаца, са израженом аутохтоном дарданско-трибалском компонентом (*Timachi*) и придошлица, које су се доселиле у више таласа од последње четвртине III до прве половине V века. Дошљаци су увек пристизали са леве обале Дунава, било из напуштене романизоване Дакије или са федератске територије у Тракији, о чему сведоче изражени елементи материјалне културе типа Черњахов – Синтана де Муреш. Ова популација је била интегрисана, што се види по дистрибуцији гробова на касноантичкој некрополи Слог у све три фазе (план 2). Грбови су, највероватније, груписани према породичним везама, а не по етничкој припадности или на основу социјалног статуса. Ово закључујемо на основу чињенице да се елементи „варварске“ материјалне културе јављају спорадично, па се пре може говорити о варваризацији становништва Тимакум Минуса него о стационарању војних јединица састављених од варвара, Гота, Алана или Хуна. С друге стране, социоекономски положај становништва сахрањеног на некрополи Слог је веома уједначен и може се описати као веома скроман. Ипак, мушкарци сахрањени у анализира-

ним војничким гробовима су већином доживели зрело доба, упркос честом рањавању и веома тешким повредама, као и траговима напорног војничког позива. Није могуће утврдити да ли се ради о умировљеним војницима, ветеранима, или о активним ратницима, али се на основу индивидуе од око 20 година, сахрањене у гробу 108, која је већ имала трагове тешких рањавања и патолошке промене изазване ношењем терета и претераним пешачењем, види да су веома рано ступали у војну службу. У II–III веку *Timacum Minus* је био привлачно место за насељавање ветерана, због природних ресурса у околини, плодног земљишта и рудних богатстава, о чему сведоче епиграфски натписи на надгробним и вотивним споменицима.

Ратници сахрањени на касноантичкој некрополи Слог припадали су коњичкој јединици, о чему сведоче карактеристични маркери стреса на остеолошком материјалу посебно у случају покојника сахрањених у гробовима 15, 76, 91, 100, 102, 108, 123 и 141. Највероватније се ради о лакој коњици стрелаца (гробови 15, 25, 76, 91, 99, 100, 102, 108, 123 и 141), која је могла да парира сличним варварским одредима. То се види, с једне стране, према повредама индивидуа из гробова 15, 26, 76, 91, 99, 100, 102, 108 и 123, а, с друге, према оружју положеном у гробове 27, 97 и 102. У случају

покојника из гробова 27 и 97, то су тробриде и листолике стрелице (Т. VI, 5, Т. VII, 3, 5–6). Без обзира на релативно сиромаштво становника касноантичког Тимакум Минуса, војничка популација сахрањена на некрополи Слог је, поред свих тешкоћа ратничког живота, имала веома добру и ефикасну лекарску заштиту, јер је већина тешких повреда санирана без већих последица по здравље и живот (Т. IV, 1; Т. VIII, 1–3; Т. XI, 1–3; Т. XII, 1–3). Ово показује да је утврђење *Timacum Minus* имало једног или више војних хирурга. О службовању лекара у овом утврђењу у претходном периоду сведочи надгробни споменик лекара II Аурелијеве кохорте Дарданаца, Тита Елија Мартијала. Такође, из Равне потиче вотивни споменик Ескулапу, који је заштитник лекара и видара, као и више медицинских хируршких инструмената (сл. 2).

Анализа војничких гробова са некрополе Слог потврдила је резултате ранијих истраживања касноантичког периода у источној Србији, односно у римској провинцији Приобалној Дакији (*Dacia Ripensis*), као и хипотезу о посадама лаке коњице у утврђењима Тимочке зоне. Карактеристике касноантичке материјалне културе ове области су милитаризација, варваризација, христијанизација и рурализација, што представља увод у раносредњовековни период.

¹ Petković et al. 2005.

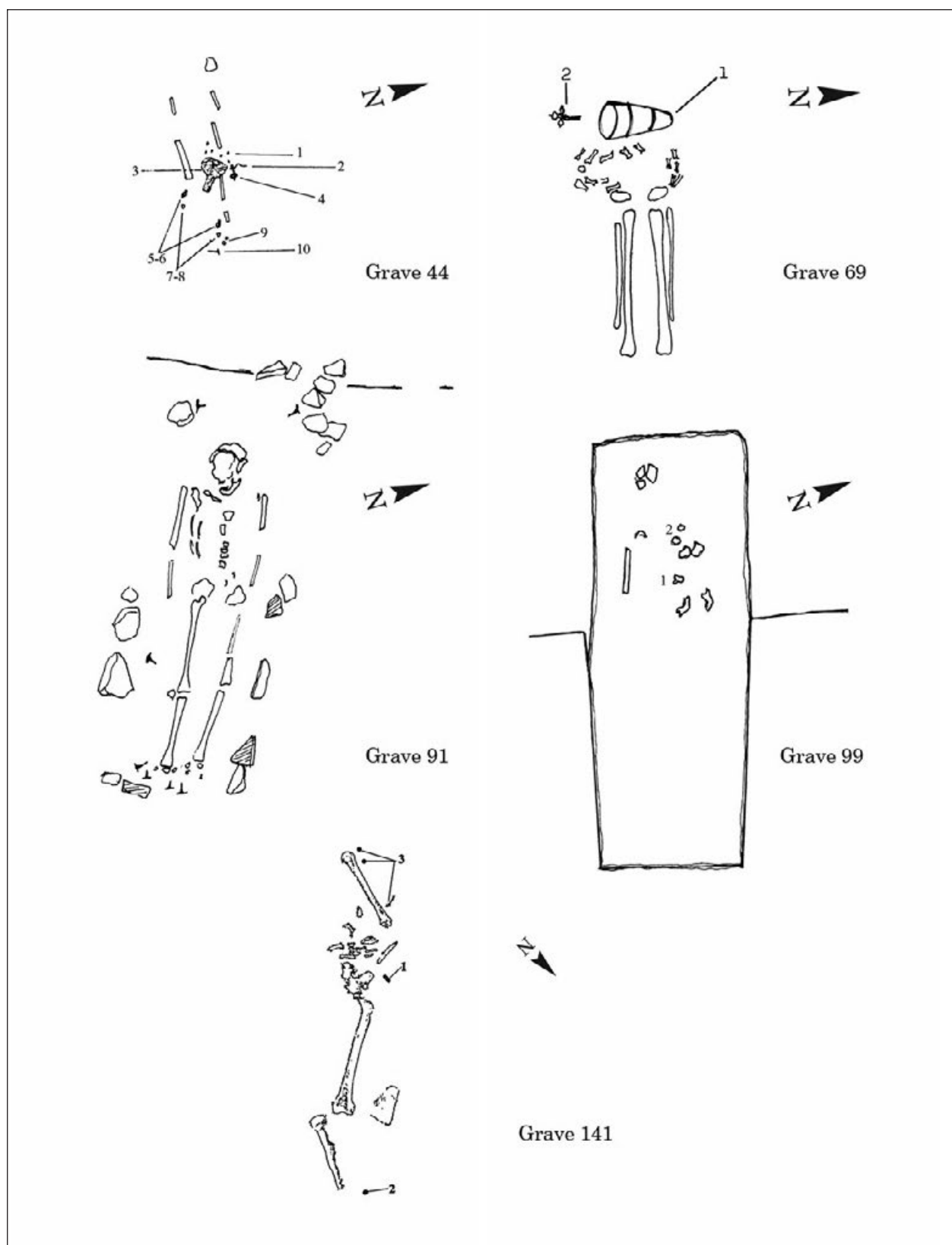


Plate I – Graves from phase I of the Late Roman Slog necropolis (350–380)

Табла I – Грбови I фазе касноантичке некрополе Слої (350–380. године)




Plate II – Grave finds from phase I of the Late Roman Slog necropolis (350–380):
 1) bronze crossbow fibula from grave 44; 2) bronze belt buckle from grave 44; 3) bronze shoe buckle from grave 44;
 4) bronze shoe strap-end from grave 44; 5) conical glass goblet from grave 69A; 6) bronze crossbow fibula
 from grave 69A; 7) silver plating of a belt set from grave 141

Табла II – Налази из гробова I фазе касноантичке некрополе Слој (350–380. године):
 1) крстообразна бронзана фибула из гроба 44; 2) бронзана појасна копча из гроба 44; 3) бронзана копча
 обуће из гроба 44; 4) бронзани језичак обуће из гроба 44; 5) стаклени конични пехар из гроба 69А;
 6) крстообразна бронзана фибула из гроба 69А; 7) сребрна ојлајта појасне тарнишуре из гроба 141

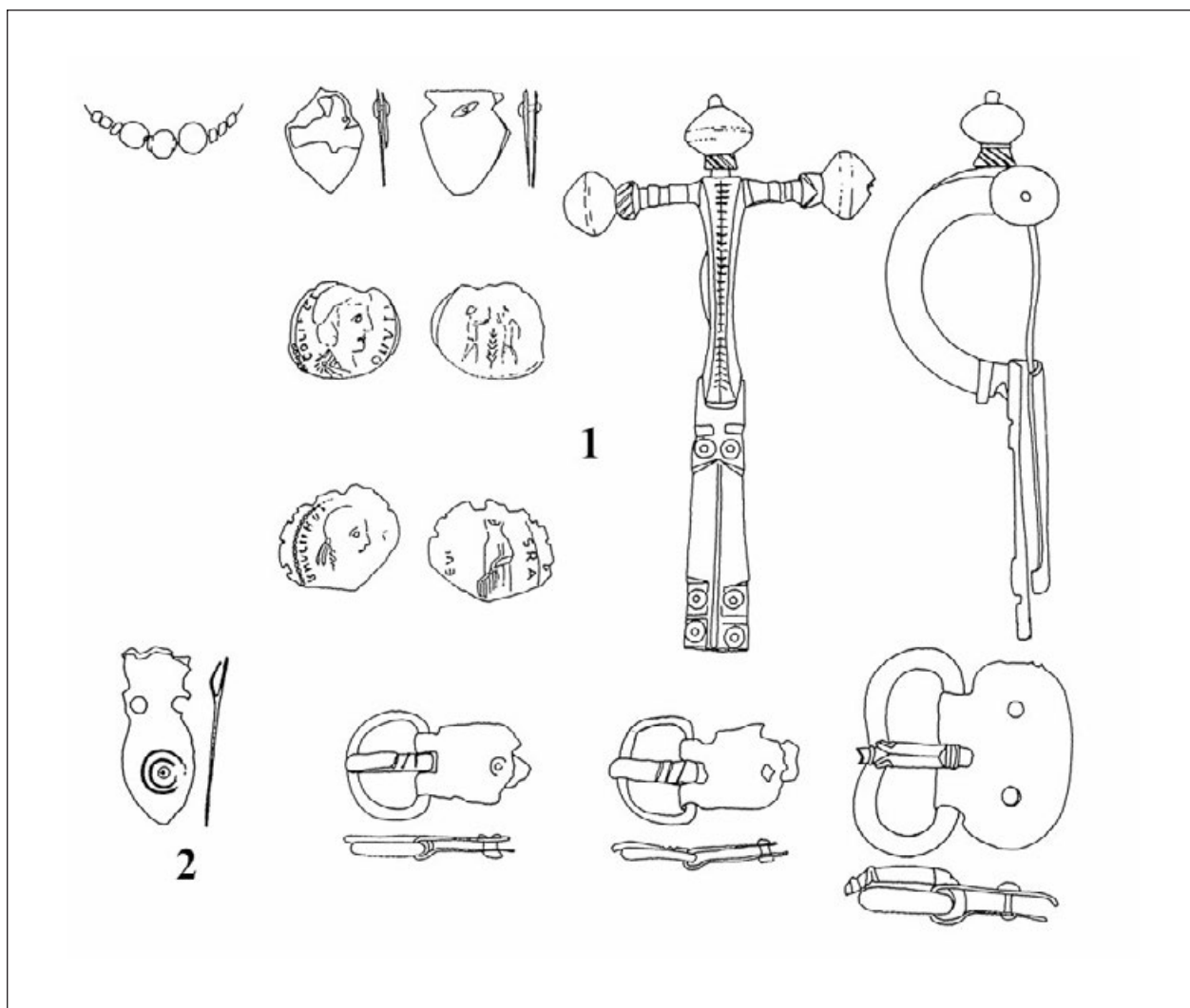


Plate III – Grave finds from phase I of the Late Roman Slog necropolis (350–380):
1) finds from grave 44; 2) bronze belt-end of a belt set from grave 99

Табла III – Налази из гробова I фазе касноантичке некрополе Слој (350–380. године):
1) налази из гроба 44; 2) бронзани језичак појасне тарнијуре из гроба 99

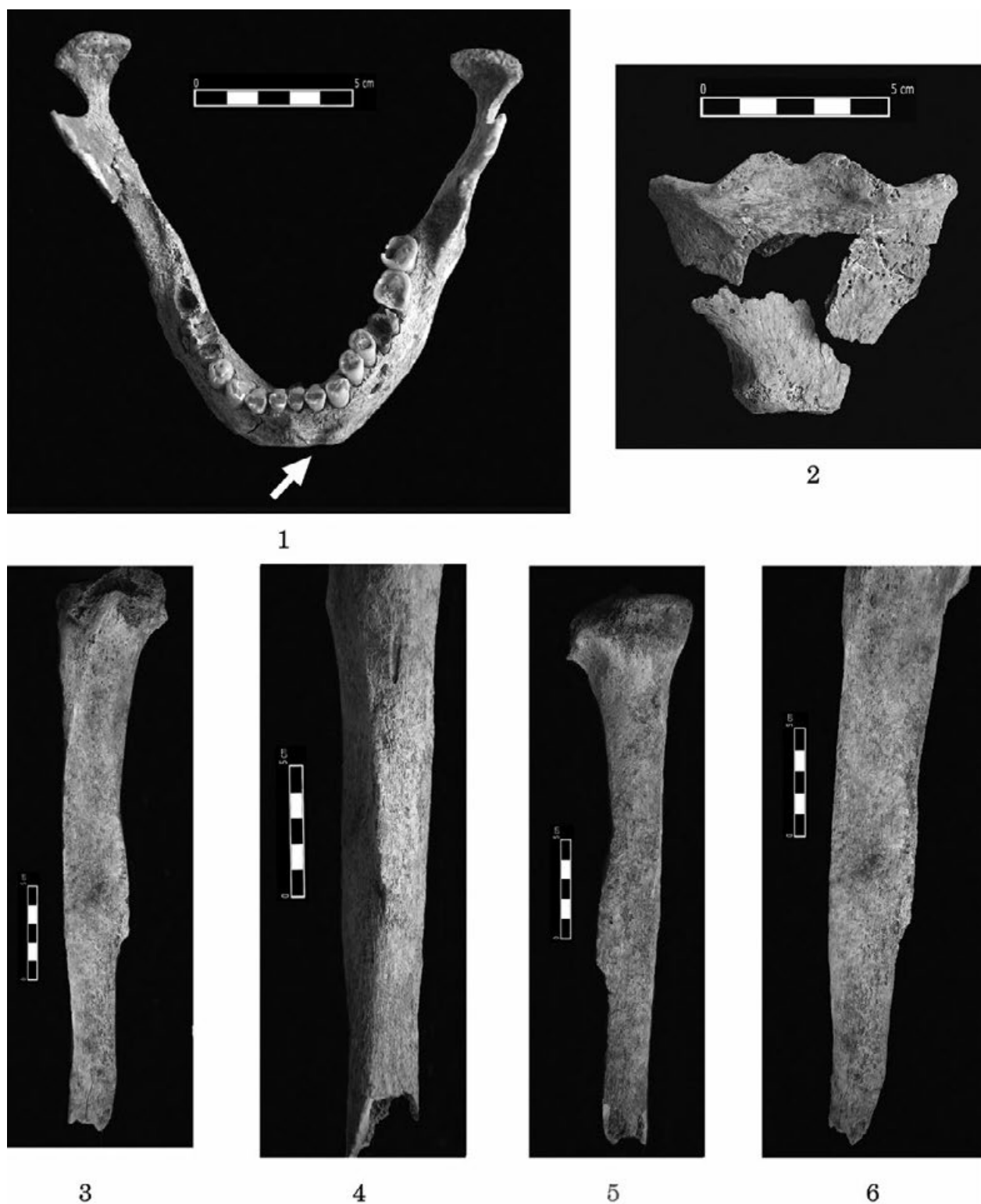


Plate IV – 1) grave 91 – cut on the left side of mentum; 2) grave 91 – pronounced muscle attachment points on manubrium; 3–6) grave 141 – myositis ossificans traumatica on left tibia

Табла IV – 1) гроб 91 – посекојина са леве стране ментума; 2) гроб 91 – истакнутиа мишићна хвашишћа на манубријуму; 3–6) гроб 141 – myositis ossificans traumatica на левој тибиији

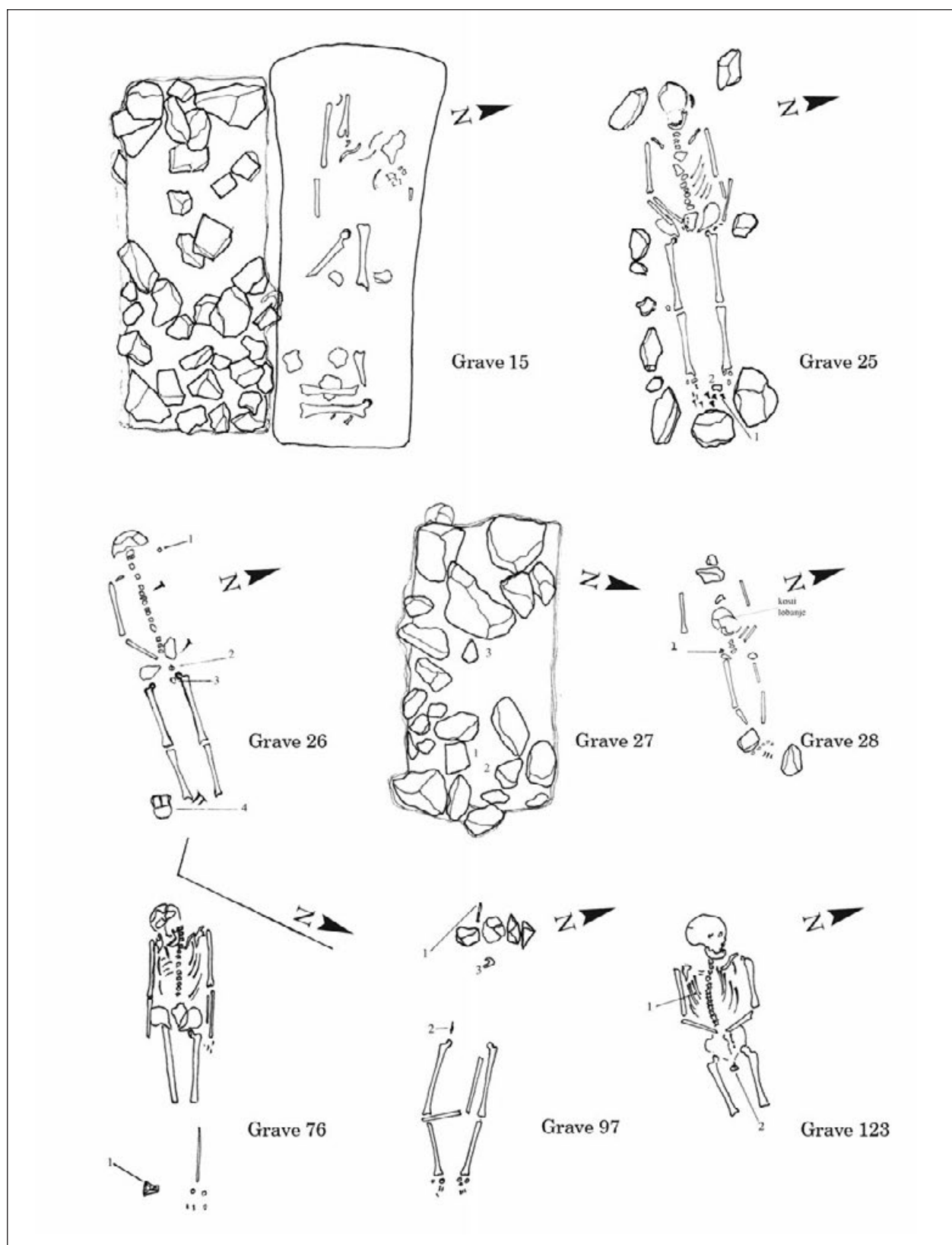


Plate V – Graves from phase II of the Late Roman Slog necropolis (380–410)

Табла V – Грбови II фазе касноантичке некрополе Слог (380–410. године)




1



2



3



5



4

*Plate VI – Grave finds from phase II of the Late Roman Slog necropolis (380–410):
1) iron belt buckle from grave 25; 2) small vessel with three handles from grave 26;
3) bronze belt buckle from grave 27; 4) conical glass goblet from grave 76;
5) tri-bladed iron arrowhead from grave 123*

*Табла VI – Налази из гробова II фазе касноантичке некрополе Слој (380–410. године):
1) гвоздена појасна копча из гроба 25; 2) лончић са три дршке из гроба 26;
3) бронзана појасна копча из гроба 27; 4) стаклени конични пехар из гроба 76;
5) шробрида гвоздена стрелица из гроба 123*

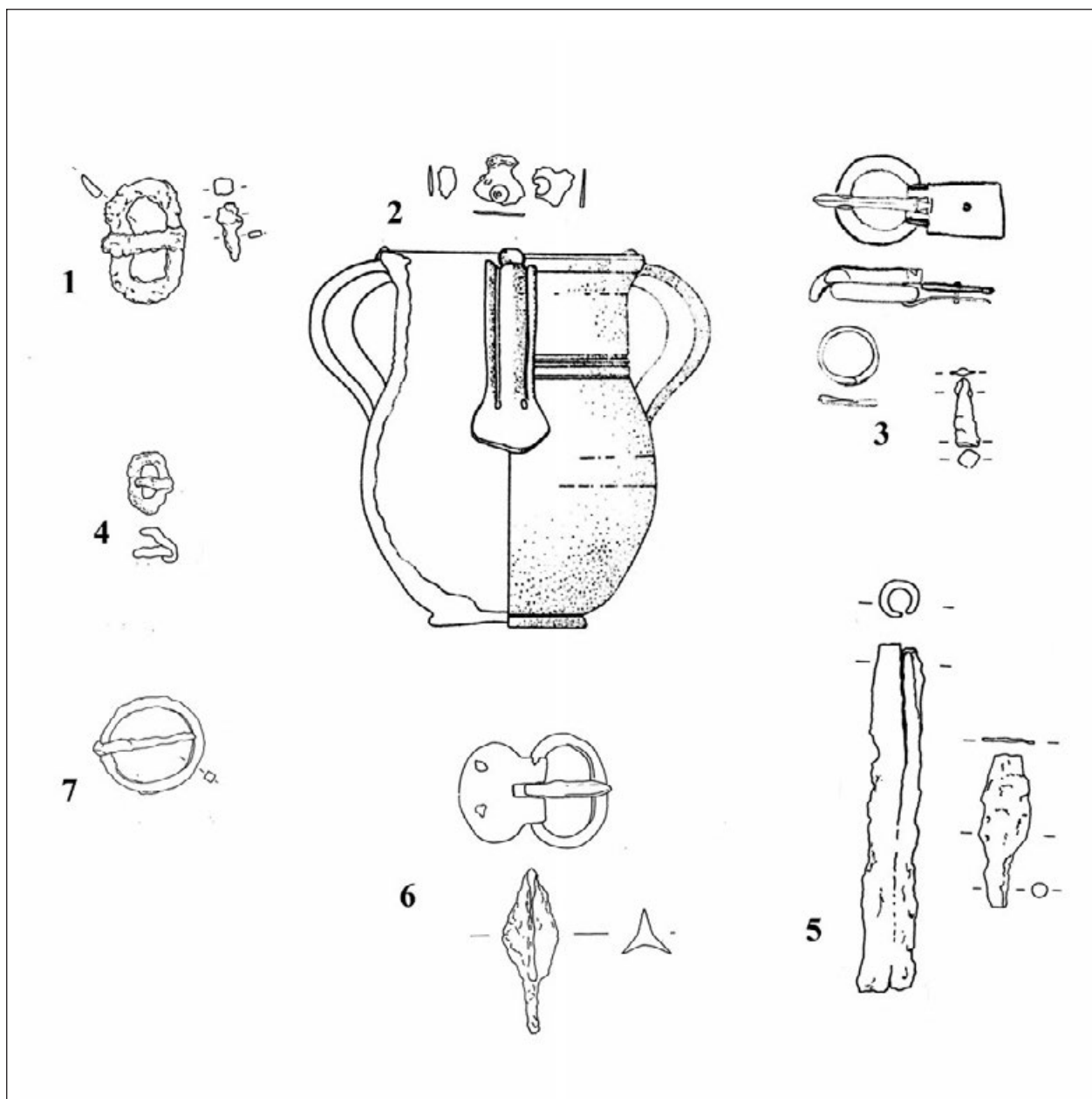


Plate VII – Grave finds from phase II (380–410) and phase III (410–450) of the Late Roman Slog necropolis:
 1) iron buckle from grave 25; 2) finds from grave 26; 3) finds from grave 27; 4) iron buckle from grave 28;
 5) finds from grave 97; 6) finds from grave 123; 7) iron buckle from grave 102.

Табла VII – Налази из гробова II (380–410. године) и III фазе (410–450. године) касноантичке некрополе Слој:
 1) њвздена којча из гроба 25; 2) налази из гроба 26; 3) налази из гроба 27; 4) њвздена којча из гроба 28;
 5) налази из гроба 97; 6) налази из гроба 123; 7) њвздена којча из гроба 102

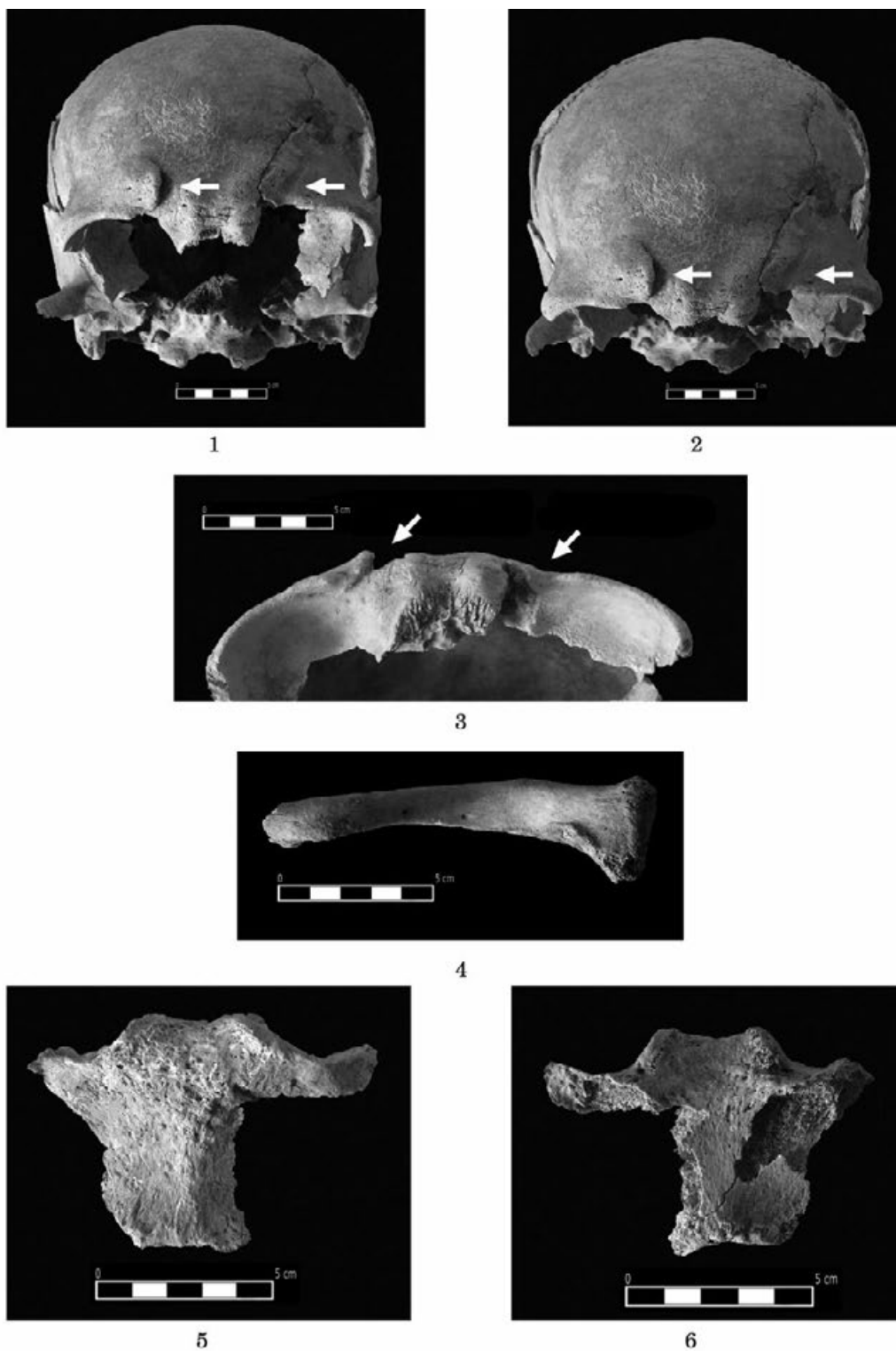
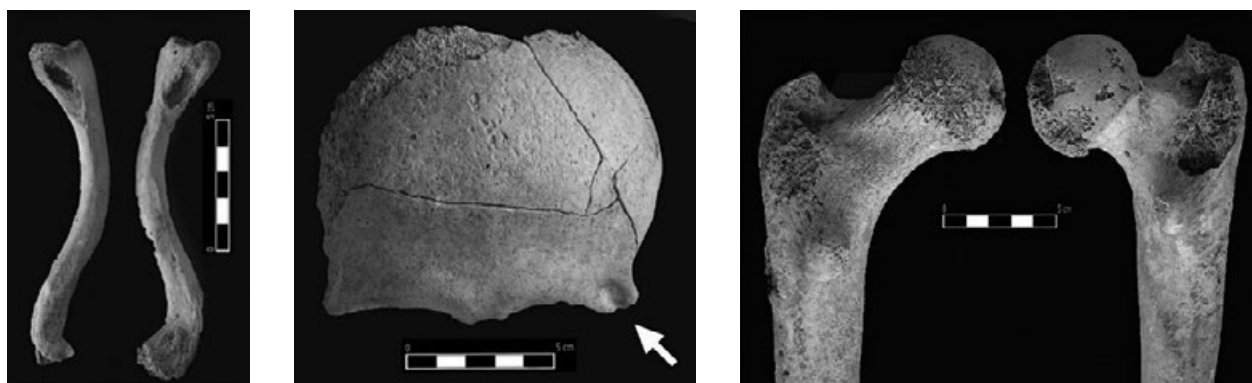


Plate VIII – 1, 2, 3) grave 15 – injuries on frontal bone inflicted by a sharp blade;
 4) grave 15 – flattened body of the clavicle (direction: superior-inferior);
 5, 6) grave 15 – incisura clavicularis on the manubrium extended to the left.

Табла VIII – 1, 2, 3) гроб 15 – повреде на фронталној кости нанете оштрим сечивом;
 4) гроб 15 – сљошћеност тела клавикуле (правац: superior-inferior);
 5, 6) гроб 15 – развучена incisura clavicularis на манубријуму у левој страни



1

2

3

Plate IX – 1) grave 25 – pronounced ligament attachment points on clavicles (lig. costoclaviculare);
 2) grave 26 – trace of injury on the left processus zygomaticus inflicted by a blunt object;
 3) grave 76 – fused fracture of the head of right femur

Табла IX – 1) гроб 25 – изражена хваїишиїа лиїаменаїїа на клавикулама (lig. costoclaviculare);
 2) гроб 26 – шраїї повреде нанеїїе шїуйїм їредмеїїом на левом processus zygomaticus-у;
 3) гроб 76 – срасла фракїїтура главе десної фемура

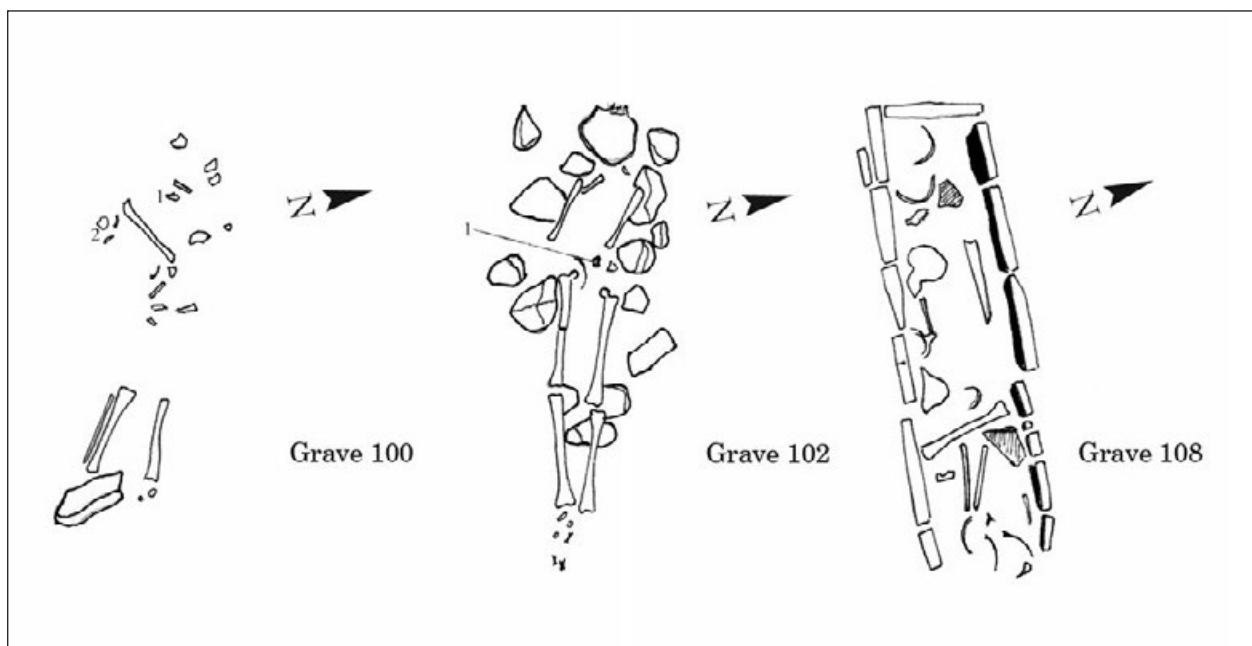


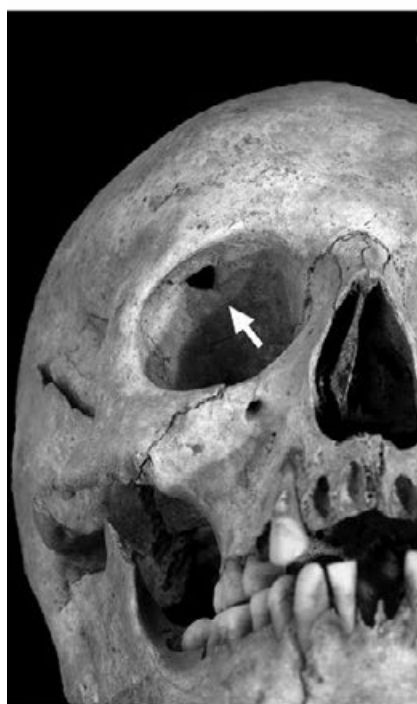Plate X – Graves from phase III of the Late Roman Slog necropolis (410–450).

Табла X – Грбови III фазе касноантичке некрополе Слої (410–450. їодине)

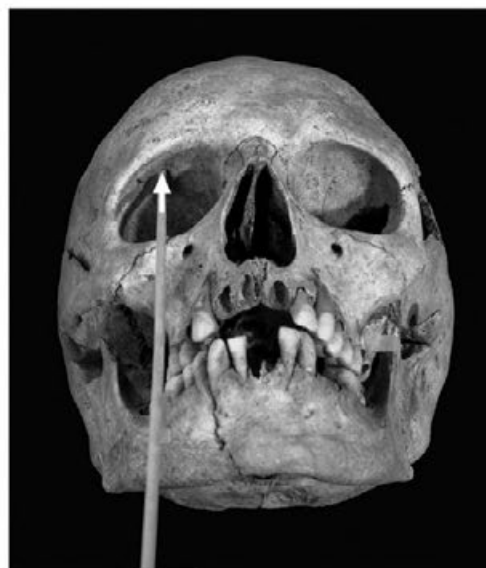

Plate XI – 1, 2) grave 100 – irregularly fused fracture of right fibula in the upper quarter of its body;
3) grave 102 – injuries on frontal bone; 4) grave 102 – irregularly fused rib fractures; 5) grave 102 – pronounced
muscle attachment points on right ulna; 6, 7) grave 102 – pronounced muscle attachment points on right femur

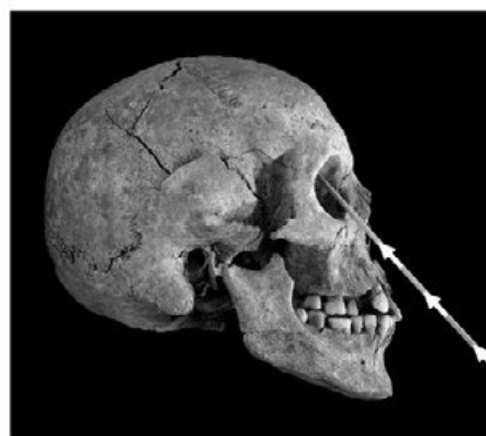Табла XI – 1, 2) гроб 100 – неправилно сраслао прелом десне фибуле у горњој четвртини шела; 3) гроб 102 –
неправилно сраслао прелом ребара; 4) гроб 102 – повреде на фронталној кости; 5) гроб 102 – истакнућа
мишићна хвајшица на десној ули; 6, 7) гроб 102 – истакнућа мишићна хвајшица на десном фемуру



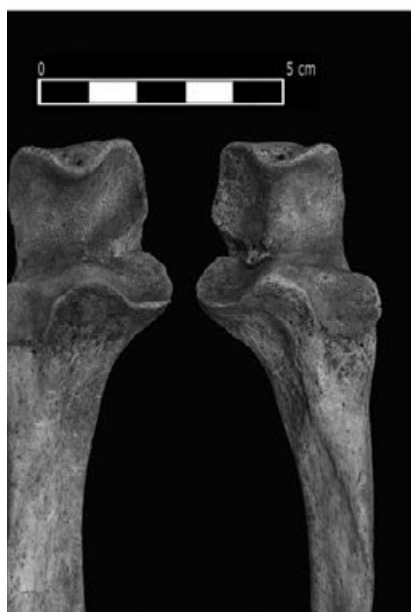1



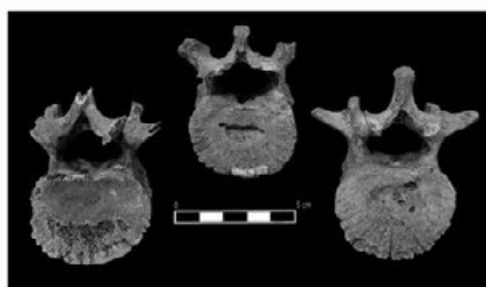
2



3



4



5

Plate XII – 1, 2, 3) grave 108 – injury inflicted by a tri-bladed arrow with traces of healing;

4) grave 108 – pronounced muscle attachment points on ulnas;

5) grave 108 – Schmorl's nodes on one thoracic and two lumbar vertebrae

Табла XII – 1, 2, 3) гроб 108 – повреда нанета шробридом стрелом, са шраповима зацељења;

4) гроб 108 – истакнућа мишићна хвајтишћа на улнама;

5) гроб 108 – Шморлови дефекти на једном грудном пршљену и на два слабинска пршљена